

# A Review of Hair Follicle Embryology, Anatomy, and the Follicular Cycle

Laura Maria Andrade Silva<sup>1\*</sup>, Ricardo Hsieh<sup>2</sup>, Silvia Vanessa Lourenço<sup>3</sup>, Bruno de Oliveira Rocha<sup>1</sup>, Ricardo Romiti<sup>4</sup>, Neusa Yuriko Sakai Valente<sup>4,5</sup>, Alessandra Anzai<sup>4</sup> and Juliana Dumet Fernandes<sup>1</sup>

<sup>1</sup>Department of Dermatology, Magalhães Neto Outpatient Clinic, Professor Edgar Santos School Hospital Complex, The Federal University of Bahia (C-HUPES/UFBa), Salvador/BA-Brazil

<sup>2</sup>Institute of Tropical Medicine of São Paulo, The University of São Paulo (IMT/USP), São Paulo/SP-Brazil

<sup>3</sup>Department of Stomatology, School of Dentistry, The University of São Paulo (FO/USP), São Paulo/SP-Brazil

<sup>4</sup>Department of Dermatology, University of São Paulo Medical School, The University of São Paulo (FMUSP), São Paulo/SP-Brazil

<sup>5</sup>Department of Dermatology, Hospital of the Public Server of the State of São Paulo (IAMSPE), São Paulo/SP-Brazil

\*Corresponding author: Laura Maria Andrade Silva, Department of Dermatology, Magalhães Neto Outpatient Clinic, Professor Edgar Santos School Hospital Complex, The Federal University of Bahia (C-HUPES/UFBa) Salvador/BA-Brazil, Tel: +55(71)3283-8380; +55(71)99981-7759; E-mail: contato@dralauraandrade.com

Received: Sep 05 2024; Accepted: Oct 12 2024; Published: Oct 18, 2024; DOI: 10.59462/jshc.1.2.108

**Citation:** Silva LMA, Hsieh R, Lourenço SV, Rocha BO, Romiti R, et al. (2024) A Review of Hair Follicle Embryology, Anatomy, and the Follicular Cycle. Journal of Skin Health and Cosmetics, 1(2):108.

**Copyright:** © 2024 Silva LMA, et al. This is an open-access article distributed under the terms of the Creative Commons Attribution License, which permits unrestricted use, distribution, and reproduction in any medium, provided the original author and source are credited.

## Abstract

The presence of hair follicles is one of the main characteristics of mammals. In each new follicular cycle, the embryonic developmental steps are repeated to form a new hair. It is a complex structure, its functions ranging from temperature regulation, physical protection, camouflage, and social interactions. In addition, it is also an endocrine organ capable of producing and locally converting many hormones. In this review, we will describe the main anatomical, embryological, and physiological properties of the hair follicle, as well as their clinical importance.

**Keywords:** Hair; Follicle; Embryology; Anatomy; Cycle

## Literature Review

### Introduction

The presence of hair follicles is one of the main characteristics of mammals. Their functions range from temperature regulation, physical protection, camouflage, sensory and tactile activity, dispersion of sebum and sweat, in addition to being important in social interactions [1,2].

The psychosocial importance of hair in society is intense, many diseases that lead to hair loss, or hair over-abundance, generate considerable morbidity, creating a demand for development of drugs that are capable of restoring hair growth and improving the appearance of hair [1].

Human skin contains approximately 5 million hair follicles, of which 100,000 are found on the scalp [3]. Hair is made by cells called trichocytes, which form a filiform keratinized structure called the hair shaft. There are three main types of hair: lanugo hair, vellus hair, and terminal hair. These differ in their pigmentation and structure, but follow the same principles of formation and development [3].

Lanugo hair is present during fetal development and in the post-natal period, and is structurally similar to the thin and lightly undeveloped hair found in adults called vellus hair. Terminal hair is the thick and pigmented hair found in the beard and the axillary and pubic regions [4]. Keratin is the main component of hair, being comprised of amino acids such as cysteine, arginine, and citrulline; citrulline is exclusively found in humans [4].

The purpose of this review is to describe the most important aspects of hair follicle development, anatomy, physiology, the relationship with associated diseases.

### Hair follicle embryology, anatomy, and molecular control

Hair follicles begin to develop early during the fetal period, mainly around the 9<sup>th</sup> and 12<sup>th</sup> week of gestation. They originate because of the proliferation of the germinative layer of the epidermis and extend to the underlying dermis [5].

When primitive hair adopts a club shape and around the 14<sup>th</sup> gestational week, the hair bulbs are already formed [5]. The epitheliocytes that form the hair bulbs will form the germinative matrix, which will later produce the hair shaft [6] (Figure 1).

Subsequently, there is an invagination of the hair bulbs by the mesenchymal papillae. Thus, the peripheral cells of the primordial hair follicles form the root sheaths and the mesenchymal cells form the dermal sheaths. The germinative matrix proliferates, pushing the cells towards the surface, where they become keratinized, forming hair [7]. Fetal hair does not appear in all regions at the same time, they may be first observed in the eyebrows, upper lip, and mental region [7,8]. At the 20<sup>th</sup> week of intrauterine life, the fetal body is lined with soft hair, referred to as lanugo, which helps with the retention of the cheesy vernix on the skin [9]. At this time, there is no difference in number of fetal hair in women or men, secondary differences between them will happen later in puberty [8]. Hair follicles do not form *de novo* in adult skin, as the absolute number is established in fetal period and a density dilution occurs along the growth of body surface [8].

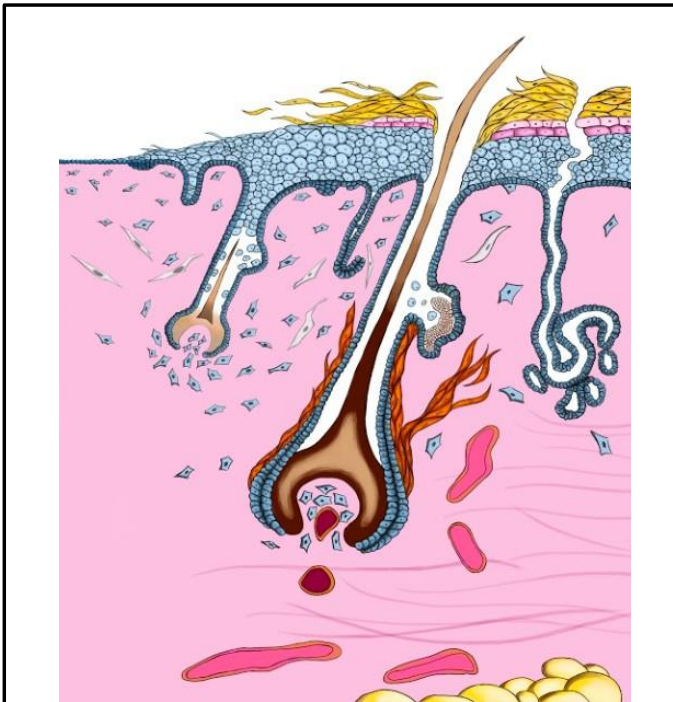


Figure 1: Schematic figure shows hair follicle's chronologic development since undifferentiated epidermis, placode, hair germ, hair peg/Bulbous peg and primitive hair follicle around 24 weeks of gestational age (Autorial figure adapted from [5]).

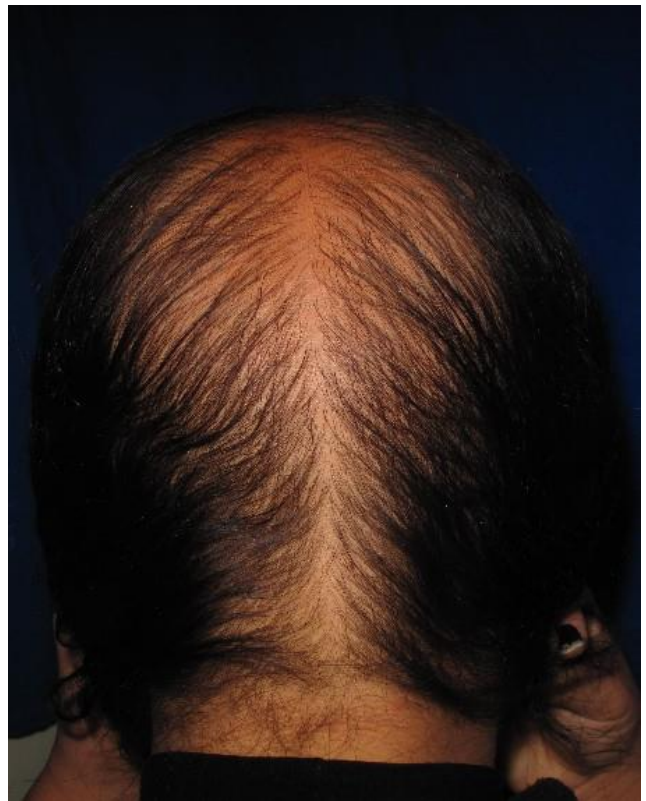


Figure 2: A woman with alopecia due to Vitamin D-Dependent Rickets type II (VDDRII), courtesy from University of São Paulo.

The key to the development of the hair follicle is the communication between the epidermis and the mesenchyme, and this communication is essential not only for hair formation, but also for the formation of all other skin annexes as nails, teeth, and glands. Many epidermal-dermal signalling pathways are involved in these processes: the WNT/wingless family, the Hedgehog family, the TGF- $\beta$ /BMP (transforming growth factor beta and bone morphogenetic protein) family, the FGF (fibroblast growth factor) family, and the TNF (Tumor Necrosis Factor) family. Different combinations of these signals dictate the development of each annex [9].

Dermal signalling which induces the vertical arrangement of keratinocytes and their proliferation occurs in small epidermal invaginations in the dermis referred to as the placodes. Mesenchymal cells of different origins begin to interact and induce the regular formation of inter-placode spaces. However, the molecular nature of the early signalling from the dermis to the epidermis remains uncertain [9].

Vitamin D-Dependent Rickets type II (VDDRII) results from a mutation in the Vitamin D Receptor gene (VDR), which is expressed in several target organs, including the hair follicle. Full or partial alopecia is a marker of a defect in the VDR and is often one of the first symptoms noted, occurring in 2/3 of cases (Figure 2). It has been shown that inadequate differentiation of the hair follicle occurs in this disease, and it is the reason why alopecia remains in patients treated by replacement of vitamin D and calcium, however its mechanism has not been fully elucidated [10].

### Lanugo hair

Lanugo hair is thin, soft, and slightly pigmented, and appears around the 12<sup>th</sup> week of pregnancy, becoming abundant between the 17<sup>th</sup> and 20<sup>th</sup> weeks. It is replaced by the thicker hair that remains throughout life, except for the inguinal and axillary regions where it will be replaced at puberty by more pigmented terminal body hair [7].

There is a genodermatosis called hypertrichosis lanuginosa congenita in which lanugo hair persists from childhood through an adult's life (Figure 3). Since very little is known about the cause of this condition the only treatment is through genetic counselling and hair reduction therapies using lasers or electrolysis [11].

### Piloerector muscle and the sebaceous gland

The piloerector muscle is derived from the adjacent mesenchymal cells; it is attached to the hair Outer Root Sheath (ORS) and the dermal papilla. It is present in all hair follicles except those in the axillae and some areas of the face [12].

The sebaceous gland is derived from the epidermis. The cell shoots arise from the epithelial cells in the ORS of the developing hair follicles and invade the adjacent connective tissue and branch out to form the primordial alveoli and associated ducts. Disruption of the central cells of the alveoli releases an oily secretion, the sebum, which together with the desquamated epidermal cells form the vernix caseosa [12].

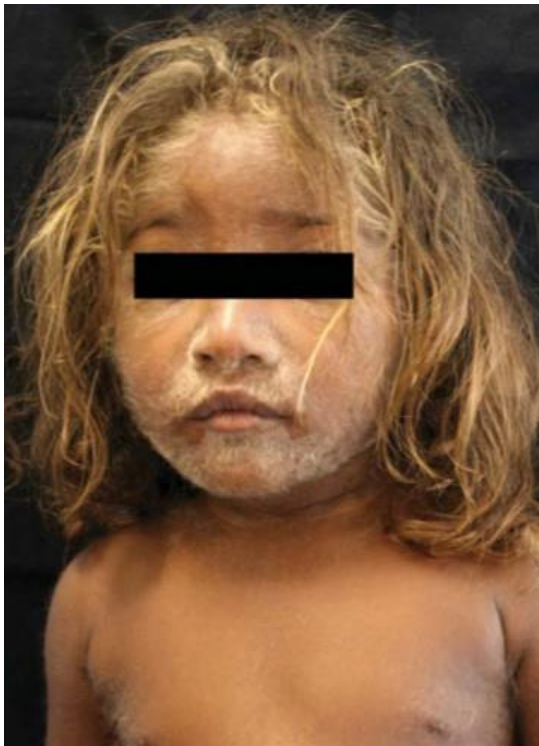

Figure 3: Child with hipertrichosis lanuginosa congenita. Dr. Silva photos-Federal University of Bahia.

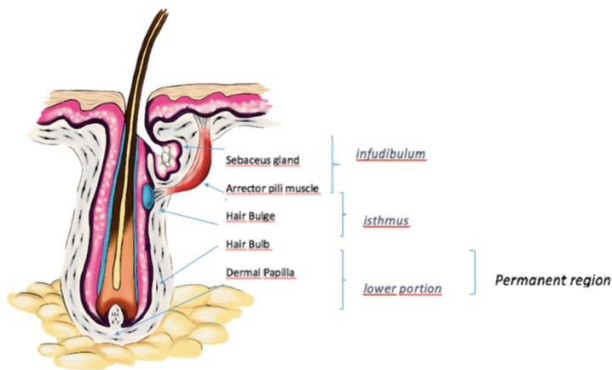


Figure 4: Pilo sebaceous's unit parts schematic draw. Permanent upper region and lower parts of hair follicle and its subdivisions (Autoral figure adapted from [3]).

Sebaceous glands can emerge in regions with or without hair and their size is inversely proportional to that of the hair present in the hair follicle [12]. They are composed of several lobes with a layer of basophilic cubic cells and another central layer of cytoplasmic rich cells that are not birefringent to polaroscopy. They are responsive to androgenic hormones, but not to neural input, remaining undeveloped until puberty. Sebum is secreted from sebaceous glands through the

process of holocrine secretion. The sebaceous glands are attached to the top hair follicle through the infundibulum [12] (Figure 4).

Scarring alopecia results from follicular damage that is sufficient to cause the destruction and replacement of the pilosebaceous structures by scar tissue. When the sebaceous glands and the arrector pili muscle are involved in hair follicle diseases they are generally associated with irreversible hair loss not only in scarring alopecias, but also in androgenetic alopecia where the loss of attachment to the arrector pili muscle is associated with irreversible hair miniaturization in the final stages of the disease [13,14].

### Arrector pili muscle

The arrector pili muscle is a small muscle bundle that runs from the hair follicle to the adjacent epidermis and dermis, contributing to the regulation and secretion of sebum [12].

The arrector pili muscle attaches to the hair follicle at the isthmus, in a region of stem cells called the follicular bulge. This muscle acts as an important factor in the integrity of the follicle, and the loss of contact between the hair follicle and the arrector pili muscle is a predictor of the irreversibility of hair loss [14]. The interaction between the dermal papilla derived mesenchyme and the follicular matrix cells, as well as the interaction between the follicular cells of the bulge and the arrector pili muscle, are essential for hair follicle integrity [14].

### Hair follicle

The hair follicle can be split into three main parts: the infundibulum, which goes from the follicular ostium to the duct that empties the sebaceous gland; the isthmus, comprising the area between the sebaceous gland duct and the insertion site of the arrector pili muscle, and finally the lower portion, which is located below the insertion site of the arrector pili muscle [12].

The hair follicle can be divided into a permanent upper portion, which surrounds the infundibulum and the isthmus, and a lower portion that is continually renewed. The lower region of the isthmus, referred to as the bulge, stores the epithelial and melanocytic stem cells, and marks the end of the permanent region [12]. These cells have a long, slow, life cycle and are able to differentiate into three structures, namely, the epidermis, hair follicles, and sebaceous glands [12].

The lower region is where the metabolically active portion of the follicle is located. The hair bulb contains the hair matrix and the dermal papilla and a small portion of richly innervated and vascularized connective tissue [12]. One of the most metabolically active cells in an organism, the keratinocytes of the follicular matrix, are found in the region of the capillary matrix in the bulb. These cells are found below the Auber line, at the largest diameter of the dermal papilla. These cells are capable of generating six different types of cells namely, the three layers of the Inner Root Sheath (IRS) and the three layers of the stem itself (Figure 5). Between these cells are active melanocytes, which, depending on the production of eumelanin or pheomelanin, will color the hair in the shade blonde or brunette. The symmetry or asymmetry of the follicular matrix is one of the determinants of hair shape resulting in either straight or curly hair [4].



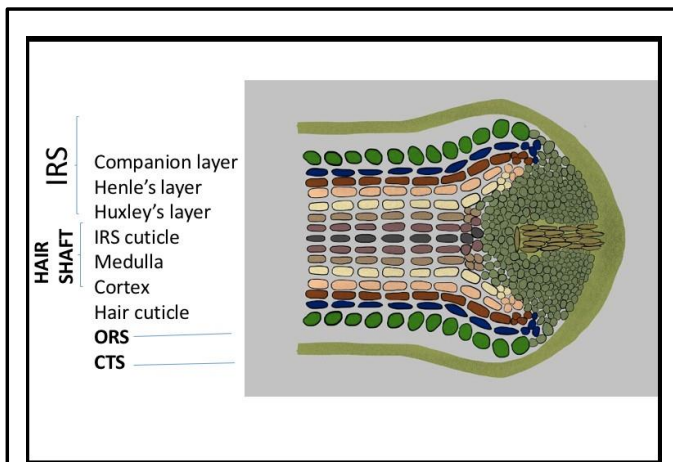
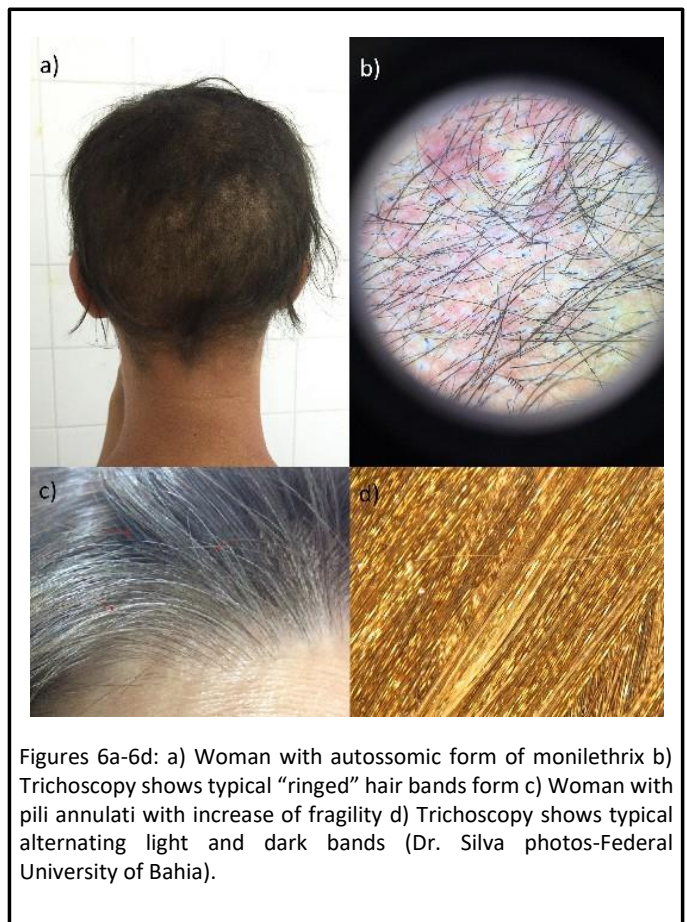


Figure 5: Hair shaft parts (IRS: Inner Root Sheath; ORS: Outer Root Sheath; CTS: Conjunctive Tissue Subcutaneous) (Autorial figure adapted from [3]).

Hair growth is directed and achieved by guiding structures and cleavage planes and an inner and hard layer of differentiated keratinocytes, referred to as the IRS, which guides and envelops the hair shaft. The IRS is formed by three layers, the Henle layer, the Huxley layer, and the cuticle. The hair shaft and the IRS move outward using a cleavage plane, the outermost portion of the outer root sheath as a companion layer. The ORS is formed by a single layer of flattened cells [4]. The ORS stretches from the epidermis to the lateral portions of the hair follicle, decreasing in thickness at greater depths. External to this sheath is a thin membrane called basal layer and in the dermis there is an arrangement of thick collagen bundles around the root of the hair follicle that constitute the fibrous root sheath [12]. While the ORS is stationary, the IRS and its accompanying sheath move with the hair shaft out of the channel [3] (Figure 5).

The hair shaft is composed of the external cuticle, the cortex, and the medulla. The cortex is composed of densely packed keratinocytes. The keratinocytes become keratinized to form the spindle, and complexed a proteinaceous layer, these keratin filaments are surrounded by a matrix rich in sulfur, giving the stem resistance and elasticity. The cortex is covered by cuticle cells that are rich in sulfur-containing proteins arranged like rows of tiles. The cuticle is responsible for maintaining the stem in the follicle. In the IRS and the capillary stem cells, the cells are strongly imbricated, which allows for hair adhesion. In the medulla, the keratinocytes are only loosely aggregated [3,12].

Primary disorders of the hair shaft, referred to as genodermatoses, are associated with hair fragility, hair breakage, and thin hair, and are caused by mutations in cytokeratins and adhesion molecules such as cadherins in some aetiologies but are not completely understood. Monilethrix and pili annulati are examples of these conditions which may be related to hair breakage [15,16] (Figures 6a-6d).



Figures 6a-6d: a) Woman with autosomal form of monilethrix b) Trichoscopy shows typical "ringed" hair bands from c) Woman with pili annulati with increase of fragility d) Trichoscopy shows typical alternating light and dark bands (Dr. Silva photos-Federal University of Bahia).

### Phases of hair follicle formation

The induction of hair follicle formation results in the placodes, which is followed by organogenesis and cytodifferentiation of the follicle; each phase has its specific molecular interactions. These three stages of development are split into eight phases [17].

In the first phase, the induction phase, a diffusion gradient between inhibitors and activators is generated by creating a proliferative field: the pre-hair germ. During the first stage of the first phase of induction, where the follicular germ is visible, the placodes are formed through the action of molecules such as Wnt/ $\beta$ -catenin, EDA-A1, NF- $\kappa$ B, Noggin, and the surrounding area inhibited by Dkk and BMPs [17].

Organogenesis, orientation of the hair follicle, occurs in the second phase. The follicular germ proliferates vertically invaginating in the dermis and the dermal papilla is formed. Later on, several molecular processes determine its polarization and the innervation of the trichocytes and germ formation. The organogenesis comprises phase 2 to phase 5, hair follicle germ and peg phase. In phase 5, IRS and the bulge can be found, and at the phase 8 all hair follicle apparatus is completely formed. Cytodifferentiation comprises phases 6 to phase 8, characterizing bulbous peg phase [3]. During cytodifferentiation, the formation of the follicular lines occurs with the development of the internal and external root sheaths and the pillar shaft, pigmentation, and the formation of the follicular bulge and the sebaceous glands [17-19].

Ue Wnt/ $\beta$ -catenin signalling pathway is the main pathway that defines the fate of the hair follicle, and its deficiency results in the absence of placodes. Ue epithelial placodes generates a signal to the mesenchyme so that it condenses and forms the dermal papilla. Ue Sonic Hedgehog signalling pathway is the major driver for the maturation and growth of the dermal papilla. Ue dermal papilla itself becomes an area of secretion and interaction with the mesenchymal cells that will eventually generate signals for the development of many follicular layers [17-19].

Not every keratinocyte becomes a trichocyte, so there are local inhibitory systems that allow for the regular and orderly distribution and development of placodes. While Wnt/EDA-A1 and Noggin are well described inducers of follicular development, the pathways involved in blocking this process have yet to be clarified. Studies in mice have shown that BMP is able to inhibit the development of placodes but not their formation [17-19].

Cytodifferentiation is characterized by development of all the compartments of the HF. Various signalling molecules are related to this process. IRS differentiation is regulated by the Gata3 and Cutl transcription factors, while BMP signalling and transcription factors such as Msx2, FoxN1 and Hoxc13 regulate hair shaft differentiation. Other factors controlling differentiation include the Dlx3 transcription factor that controls differentiation of IRS and hair shaft. Dlx3 is a direct target of Lef1 and up regulates expression of Hoxc13 and Gata3 transcription factors, regulators of hair shaft differentiation [17,20] (Figure 7).

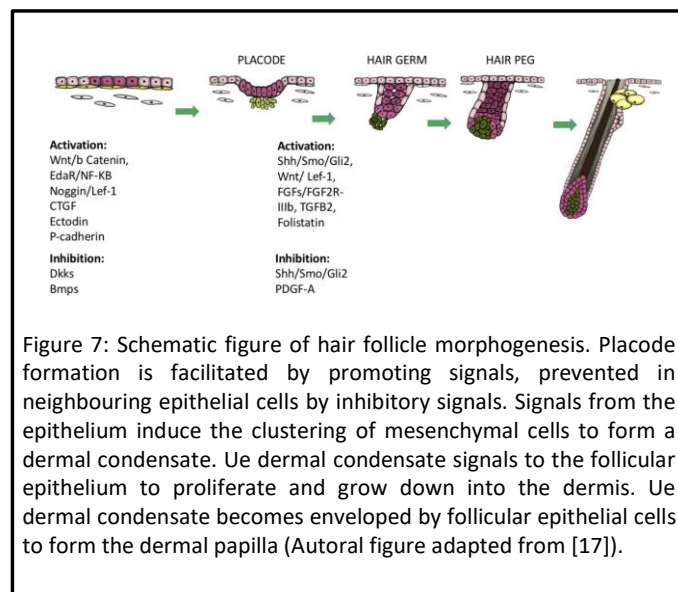


Figure 7: Schematic figure of hair follicle morphogenesis. Placode formation is facilitated by promoting signals, prevented in neighbouring epithelial cells by inhibitory signals. Signals from the epithelium induce the clustering of mesenchymal cells to form a dermal condensate. Ue dermal condensate signals to the follicular epithelium to proliferate and grow down into the dermis. Ue dermal condensate becomes enveloped by follicular epithelial cells to form the dermal papilla (Autorial figure adapted from [17]).

## Follicular Cycle

Ue hair follicles are constantly renewing themselves. Growth, regulation of growth, cellular death and destruction and tissue repairing are not clearly understood at other biological systems as they are in hair follicle [8]. Uey are alternating between biologically active phases of growth, the anagen phase, the involution phase, the catagen phase, and the rest phase, telogen. Uere is also a shedding phase called exogen [2,17-22] (Figure 8).

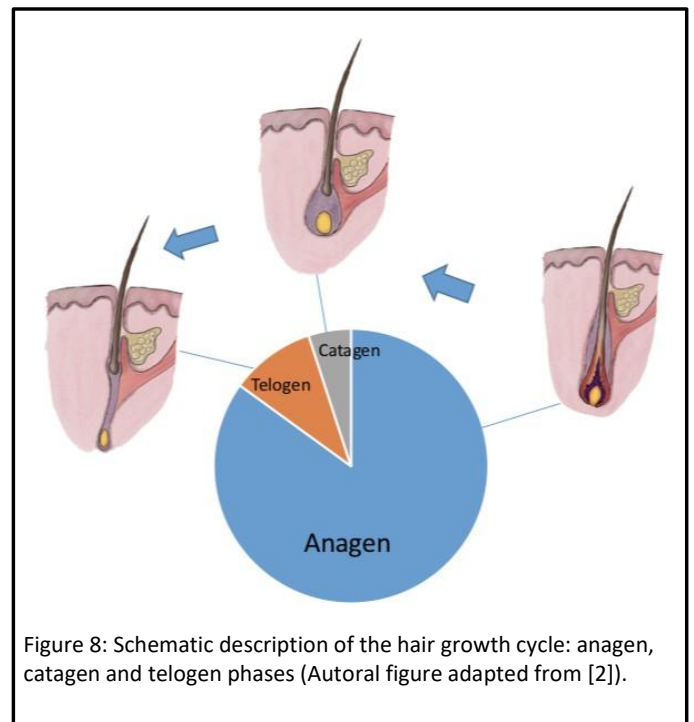


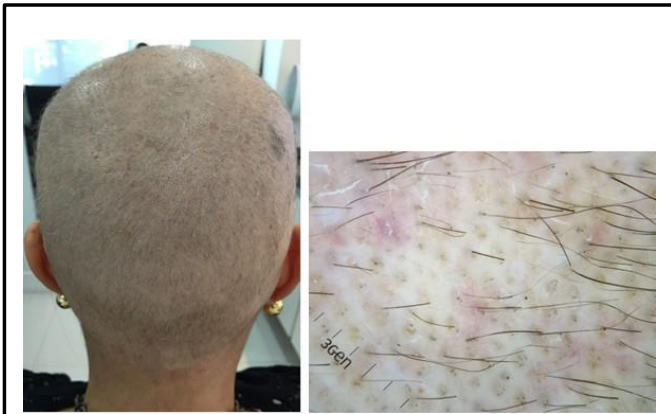Figure 8: Schematic description of the hair growth cycle: anagen, catagen and telogen phases (Autorial figure adapted from [2]).

## Anagen phase

Ue anagen phase is the period of the follicular cycle where the lower portion of the follicle regenerates alone, producing a new pillar shaft [20-22]. It can be induced by a variety of factors, including trauma and healing, although its area of stimulation is limited, and it can only stimulate the area around the trauma. Other substances that are also capable of inducing the anagen phase, include the drugs cyclosporin A, minoxidil, FK506, norepinephrine depleting agents, estrogen receptor antagonists (in mouse), and tretinoin. Many growth factors and neural mediators such as tumor promoting factor, keratinocyte growth factor, hepatocyte stimulating factor, Sonic hedgehog, substance P, capsaicin, parathyroid hormone antagonists, ACTH, and the degranulation of mast cells are able to induce anagen, although the pathways and its participation in the spontaneous induction of the signal is still unclear [20-22].

Ue anagen phase is divided into six sub-phases. Ue durations of the first five stages differ little on different scalp sites, although only the duration of the last phase is the determining factor for hair length. Ue first changes observed in the initial anagen phase are changes in the papilla and in the follicular germ. Epithelial cells in the follicular germ descend towards the dermis as an epithelial finger, guided by a fibrous tract called the stela. Uis tract is created by the first mature follicle formed and when they reach the desired depth, they change direction and rise to form the radicular sheath and the pillar rod. Ue highest mitotic rate occurs at the height of the Auber line. Ue matrix cycle lasts 23 hours in humans and has a mitotic index of 4.3%. Cylinder formation is not seen in anagen phase 1 and can only be seen at the end of anagen 3 when the hair follicle layers begin to form [20-22]. Anagen I down growth shows no cylindrical layer differentiation. At anagen III, the IRS/ORS are identifiable. At the point that the finger of epithelium reaches its deepest level and before anagen III, the layers of the follicle begin to form [22].

The term anagen effluvium refers to the abrupt loss of hairs in their growth phase due to an event that impairs the mitotic or metabolic activity of the hair follicle (Figures 9a and 9b). Chemotherapy, radiation, toxic chemicals, and sometimes inflammatory diseases such as alopecia areata and pemphigus are also capable of diminishing the metabolic activity of hair follicles resulting in anagen hair loss. Anagen effluvium is reversible, and hair regrowth occurs after a delay of 1-3 months [23].



Figures 9: (a and b) Woman with anagen effluvium due to Chemotherapy-Trichoscopy shows black dots and broken hairs (Courtesy from Dr. Anzai University of São Paulo).

### Catagen phase

The catagen phase begins when the anagen phase ends. It is a highly controlled phase where there is coordination between cellular differentiation and apoptosis, resulting in a cessation of cellular growth and in pigmentation. At this stage, the papilla is released from the bulb; there is a loss of differentiation of the lower follicle layers, a remodelling of the follicle matrix, and shrinking of the distal portion of the follicle through an apoptotic process [20-22].

Although the spontaneous signals leading to this phase are not well characterized, the many stresses that precipitate the catagen phase are well-known and include environmental and chemical factors such as trauma and dexamethasone as well as hormones such as ACTH and 17- $\beta$ -estradiol [20-22]. The catagen phase can be divided into eight sub-phases beginning at the late anagen phase and ending with the initial telogen phase [22]. The first sign is the loss of the cellular projections from fibroblasts in the basement membrane of the dermal papilla. The extracellular matrix ceases the supply of substances and the papilla shrinks, cell division in the bulbar matrix ceases, and massive apoptosis occurs in specific regions of the regressing follicle [3]. Changes also occur in cytoskeletal proteins and in the adhesion molecules trichohyalin, transglutaminase I, and desmoglein that stop being produced. Concomitantly, the lower follicle shrinks and becomes an epithelial cord [20-22]. Catagen is a highly regulated event. Its purpose is to delete the old hair structure and to bring up a new follicle utilizing the stem cells from bulge and from papilla. As catagen regression occurs by apoptosis, understanding the controls of apoptosis will be central to understanding catagen control [22].

### Telogen phase

The telogen phase is where the follicle is found in the dermis covered by quiescent epithelial cells, the papillary fibroblasts forming an epithelial sac. Later, this adopts a rod format that is adherent to the ORS. Even though it is widely known as a resting phase, it is speculated that it is a much more active phase than we are able to identify today [20-22]. The telogen phase is the third phase of hair's cycle, occurring after both the anagen phase and catagen phase. It typically lasts between three to five months. During this final stage of hair cycle the hair ceases to grow any further and becomes fully keratinized. The dermal papilla enters a resting stage and does not supply any nutrition to the hair; which is fully grown and no longer needs sustenance. This hair is called club hair and it has matured and no longer has access to the blood supply because there is no longer a need to grow. The hair bulb is made of keratin and is ready to make an exit from the scalp [20-22].

Telogen Effluvium (TE) is the most common cause of hair loss; it is a heterogeneous disorder that can be classified into three main categories: premature teloptosis, collective teloptosis, and the premature entry into telogen induced by drugs. TE can also be caused by dietary deficiencies and an "autoimmune" response. It is a self-limited condition such that hair regrowth occurs after 3 to 9 months [24].

### Exogenous phase

In animals, it is common for hair to grow before the previous hair falls out, mainly for protective reasons. In humans, the anagen and telogen phase are events that are independent of the exogenous phase. This requires an innate control of hair falling out process and a local apparatus responsible for this. In mammals, temperature, nutrition, genetic, and systemic factors are all involved in hair fallout. The adhesion of the hair follicle in the canal is influenced by the presence of many factors such as desmogleins, enzymes such as cathepsin L, and lipids. Mice with specific deficiencies in any of these factors, and patients using the protease inhibitor class of drugs, suffer from hair loss. Problems at this stage lead to the retention of many strands, causing dilation of the infundibulum, a condition seen in a pathology called trichostasis spinulosa. In androgenetic alopecia the opposite occurs, there is an early exogenous phase, with one strand falling out before the next anagen phase starts. Although it is believed that the anagen and exogenous phase are separate events they are connected in some way, but the exact mechanisms of how this occurs is not yet known [20-22].

In each new cycle a new hair is formed, and its formation depends on the activation of epithelial stem cells found in the bulge. The hair follicle is sensitive to many cytokines, growth factors, neuropeptides, and hormones that are often produced by the hair follicle itself, although the hair cycle is an autonomous phenomenon capable of continuing alone in the culture of isolated cutaneous follicles [2,20-22]. The basis for this continuous regeneration is the interactions between the follicular unit and the mesenchyme. Some molecular signals have already been defined as follicular cycle markers and regulators such as fibroblast growth factor, transforming growth factor, and Wnt signalling, Sonic Hedgehog, neurotrophins, and homeobox proteins [22].

The reasons why the hair follicle cycles are obscure, but it is speculated that cycling controls the size of the hair in each place, to promote the fall of the rods to help maintain skin cleanliness, adaptation to climatic conditions, social conditions, and incorrect

formation of the follicle, and malignant degeneration that may occur due to increased mitotic process [20-22]. In humans and guinea pigs the hair follicles have a unique individual and asynchronous cycle. Despite its autonomic functioning, the follicular cycle is influenced by environmental and local factors, the surrounding follicles, and endocrine stimuli [20-22].

## Neuromodulation

The nervous system acts directly or indirectly in the control of the follicular cycle although it is difficult to establish the piloneural communication routes [23-25]. Neurotrophins and their receptors are key elements in follicular formation and its cycle. The hair follicle is the source and target of neurotrophins, neurotensins, and brain neurotrophic factor. Neurotrophins are prominently expressed in the isthmus and bulge region by Shwann cells and stimulate their receptors in the follicle and mesenchyme. The neurotrophins produced by the capillary cycle are able to remodel their innervation and alter the follicular cycle to influence the parafollicular cells in addition to mast cells and macrophages [22,25]. Neuroendocrine control is established by hormones produced at a distance such as prolactin, melatonin, and ACTH, as well as hormones produced by the pilosebaceous unit itself namely, corticotropin releasing hormone, beta endorphin, and alpha melanocyte stimulating hormone [22,25].

Physical and psychological stresses may lead to disturbances in the capillary cycle. Examples include the hemi-hypertrichosis seen after thoracic surgery secondary to parasympathetic hyperinnervation, the canities subita phenomena seen in Marie Antoinette syndrome, and the abrupt hair fall out in a severe telogen effluvium are examples. Beta adrenergic receptors can be found in the bulge region in the early anagen phase and substance P can induce both anagen and catagen phases [22,25-27].

## Immune system

It is possible that changes in the location and amount of immune cells, such as mast cells and macrophages, have an impact on the cell cycle. Abnormal forms of hair loss are reversibly mediated by immune cells when they affect the bulb (alopecia areata) and are irreversible when they attack the isthmus and bulge (cicatricial alopecia). Immuno-modulatory drugs such as cyclosporin induce the anagen phase whereas corticosteroids induce the catagen phase in rodents [22]. Mast cell activity also has relevance in the follicular cycle, where mast cell degranulation can induce both the anagen and catagen phases in mice, and mouse with a deficiency in mastocyte c-kit signalling protein have a delayed catagen phase [20-27].

## Conclusion

The hair follicle is a fantastic mini organ with structural, endocrine, and social functions. The more we study this mini-organ the more we realize how complex its development and its interrelations with the other components of the skin are. Numerous studies have tried to understand its physiology in order to find possible therapeutic targets, but currently so little is known that we expect this to be a significant area of research in the future.

## References

1. Binder M (2000) Handbook of Diseases of the Hair and Scalp. BMJ 321:1026
2. Paus R, Cotsarelis G (1999) The biology of hair follicles. N Engl J Med 341: 491-497.
3. Bologna JL, Jorizzo JL, Rapini RP (2010) Dermatology. Gulf Professional Publishing Books – Elsevier, Houston, Texas, USA.
4. Sadler TW (2015) Langman. Embriologia médica 13e. Wolters Kluwer Health.
5. Moore KL, Persaud TVN, Torchia MG (2015) The developing human - Book: Clinically Oriented Embryology. Elsevier Health Sciences, USA.
6. Carlson BM (2014) Embriologia humana e biologia do desenvolvimento. Elsevier, Brasil.
7. Schoenwolf GC, Bleyl SB, Brauer PR, Francis-West PH (2014) Larsen's human embryology. Elsevier Health Sciences, Brasil.
8. Montagna W, Ellis RA, British Society for Research on Ageing (1958) The biology of hair growth. New York: Academic Press.
9. Schneider MR, Schmidt-Ullrich R, Paus R (2009) The hair follicle as a dynamic miniorgan. Curr Biol 19: R132-R142.
10. Miksa KF, Brenner FM, Andreola GM, Sakiyama PH (2017) Alopecia in patients with vitamin D-resistant rickets type- II. An Bras Dermatol 92: 286-287.
11. Silveira L, Ramos A, Rosado I, Rego V (2013) Do you know this syndrome? An Bras Dermatol 88: 473-475.
12. Sampaio R, Rivitti E (2007) Dermatologia. São Paulo: Artes Médicas.
13. Ioannides D, Tosti A (2015) Alopecias - Practical Evaluation and management. Curr Probl Dermatol 47: 1-9.
14. Sinclair R, Torkamani N, Jones L (2015) Androgenetic alopecia: New insights into the pathogenesis and mechanism of hair loss. F1000Res 4: 585.
15. Giehl KA, Rogers MA, Radivojkov M, Tosti A, De Berker DA, et al. (2009) Pili annulati: refinement of the locus on chromosome 12q24.33 to a 2.9-Mb interval and candidate gene analysis. Br J Dermatol 160: 527-533.
16. Redler S, Pasternack SM, Wolf S, Stienen D, Wenzel J, et al. (2015) A novel KRT86 mutation in a Turkish family with monilethrix, and identification of maternal mosaicism. Clin Exp Dermatol 40: 781-785.
17. Oh JW, Kloepper J, Langan EA, Kim Y, Yeo J, et al. (2016) A guide to studying human hair follicle cycling in vivo. J Invest Dermatol 136: 34-44.
18. Hardy MH (1992) The secret life of the hair follicle. Trends Genet 8: 55-61.
19. Paus R, Foitzik K (2004) In search of the "hair cycle clock": A guided tour. Differentiation 72: 489-511.
20. Rishikaysh P, Dev K, Diaz D, Qureshi W, Filip S, et al. (2014) Signaling involved in hair follicle morphogenesis and development. Int J Mol Sci 15: 1647-1670.
21. Paus R (1998) Principles of hair cycle control. J Dermatol 25: 793-802.
22. Stenn KS, Paus R (2001) Controls of hair follicle cycling. Physiol Rev 81: 449-494.
23. Kanwar AJ, Narang T (2013) Anagen effluvium. Indian J Dermatol Venereol Leprol 79: 604-612.
24. Rebora A (2014) Telogen effluvium revisited. G Ital Dermatol Venereol 149: 47-54.
25. Paus R, Peters EM, Eichmüller S, Botchkarev VA (1997) Neural mechanisms of hair growth control. J Invest Dermatol Symp Proc 2: 61-68.
26. Paus R, Müller-Röver S, Botchkarev VA (1999) Chronobiology of the hair follicle: Hunting the "hair cycle clock". J Invest Dermatol Symp Proc 4: 338-345.
27. Stenn KS, Paus R (1999) What controls hair follicle cycling? Exp Dermatol 8: 229-233.