

Acute Demyelinating Polyneuropathy from Sarcoidosis Presenting as Guillain-Barré Syndrome: A Case Report

Dushantha Madegedara*, Asela Rasika Bandara, Sachini Seneviratne, Sajani Dharmadasa and Samadara Nakandala

Department of Respiratory Medicine, Teaching Hospital Kandy, Kandy, Sri Lanka

Abstract

Sarcoidosis is an inflammatory granulomatous disease with diverse clinical manifestations. Neurological manifestations occur in minority which can mimic many other pathologies. Sarcoid peripheral neuropathy is a heterogeneous group comprising many different clinical patterns. Acute demyelinating type of polyneuropathy masquerading Guillain-Barre Syndrome (GBS) can rarely occur due to sarcoidosis. We report a 50 year old female with recent onset symptoms of sarcoidosis developing acute demyelinating polyneuropathy mimicking GBS. Distinction between both conditions is important for appropriate management. However, this can be challenging in clinical practice.

Keywords: Sarcoidosis; Demyelinating neuropathy; Guillain-Barre syndrome

Abbreviations: GBS: Guillain-Barre Syndrome; AIDP: Acute Inflammatory Demyelinating Polyradiculopathy; CIDP: Chronic Inflammatory Demyelinating Polyneuropathy; ACE: Angiotensin Converting Enzyme; EBUS: Endobronchial Ultrasound Scanning; NCS: Nerve Conduction Studies; CSF: Cerebrospinal Fluid; IVIG: Intravenous Immunoglobulin.

Introduction

Sarcoidosis is a multisystem disorder of unknown aetiology, characterized by granulomatous inflammation [1-3]. It is reported globally among all ethnic groups, albeit having varying incidence [4]. Although it can occur at any age, the peak incidence is seen among 20-39 years [4]. Sarcoidosis can affect many organs including skin, liver, spleen, kidney, heart, bones and joints; however, lungs and the lymphatic system are most commonly involved [1,2,4].

Sarcoidosis with nervous system involvement, known as neurosarcoidosis occurs in 5%-20% of cases [3]. However, higher prevalence of neurological involvement is proven histologically even in asymptomatic individuals according to autopsy studies [1]. Neurological symptoms precede the diagnosis of sarcoidosis in up to 74% of cases of neurosarcoidosis [4]. Neurosarcoidosis is among the life threatening complications of sarcoidosis. Since, it can affect any part of the nervous system alone or in combination, resulting in various clinical manifestations, it can mimic many other diseases [2,5].

Various forms of peripheral neuropathies occur in 2%-40% of patients with neurosarcoidosis. While symmetrical axonal type sensory motor polyneuropathy is the commonest form; focal and multifocal neuropathy, polyradiculopathy and vascular neuropathy are identified among others [1]. Cases of demyelinating polyneuropathy due to sarcoidosis masquerading Acute Inflammatory Demyelinating Polyradiculopathy (AIDP)/GBS and Chronic Inflammatory Demyelinating Polyneuropathy (CIDP) have been reported rarely. We report a case of sarcoid neuropathy mimicking GBS which led to a diagnostic challenge.

Case Report

A 50 year old Sri Lankan female, resident in the United Kingdom, had presented initially with dry cough for 3 months duration. She had also noticed significant appetite loss and weight loss of 14 Kg over same period. She complained of excessive night sweating, however denied

fever. These were not associated with any shortness of breath, wheezing, chest pain, palpitations or ankle edema. She felt increasingly fatigue over this period, however denied any blood loss, myalgia or arthralgia. There were no significant complaints related to neurological, renal or gastrointestinal systems at the onset. Her past medical history revealed diabetes mellitus, which was well controlled on Metformin only.

Her initial investigations revealed hemoglobin of 13 g/L (11.5-16.5), white cell count $5.1 \times 10^9/L$ (3.0-10.0) with normal differentials, platelet $297 \times 10^9/L$ (150-400), serum creatinine 55 $\mu\text{mol/L}$ (44-80), Na-137 mmol/L, K-4.6 mmol/L, SGOT-24 U/L, SGPT-20 U/L (10-35), albumin 4.1 g/dL (3.2-4.5), globulin 3.2 g/dL (2.5-3.4), C-reactive protein-5.4 mg/L (0-5) and sedimentation rate 34 mm/hr. However, her chest radiograph showed right hilar prominence (Figure 1). Contrast enhanced Computer Tomography (CT) revealed multiple mediastinal and bilateral hilar lymphadenopathy, with normal lung parenchyma and pleura (Figure 2). Further investigations found following abnormal results; serum corrected calcium 2.73 mmol/L (2.2-2.6), 24 hr-urine calcium excretion 7.91 mmol (2.5-7.5), serum alkaline phosphatase 107.7 IU/L (42-98), gamma glutamyl transferase 323.8 IU/L (normal <38), serum total bilirubin 1.62 mg/dL (0.2-1.2), with direct bilirubin 0.33 mg/dL (normal <0.3). Moreover, she had greatly raised serum Angiotensin Converting Enzyme (ACE) levels up to 184 U/L (normal 0-52). She was planned to undergo Endobronchial Ultrasound Scanning (EBUS) guided lymph node aspiration, which was not conducted due to patient refusal. However, based on above investigations, she was diagnosed as a probable case of sarcoidosis and treatment commenced with high dose prednisolone. She defaulted the treatment after three weeks and obtained Ayurvedic medications from India for one month.

She presented to respiratory unit 2 of Teaching hospital, Kandy, Sri Lanka with worsening generalized weakness for one week. This

*Corresponding author: Madegedara D, Department of Respiratory Medicine, Teaching Hospital Kandy, Kandy, Central Province 20000, Sri Lanka, Tel: 0094812384374; E-mail: dmadegedara@yahoo.com

Received: Mar 04 2024, Accepted: Apr 22 2024; Published: Apr 25, 2024, DOI: 10.59462/jprd.1.1.103

Citation: Madegedara D, Bandara AR, Seneviratne S, Dharmadasa S, Nakandala S (2024) Acute Demyelinating Polyneuropathy from Sarcoidosis Presenting as Guillain-Barré Syndrome: A Case Report Journal of Pulmonary and Respiratory Diseases.1(1):103

Copyright: © 2024 Madegedara D, et al. This is an open-access article distributed under the terms of the Creative Commons Attribution License, which permits unrestricted use, distribution, and reproduction in any medium, provided the original author and source are credited.

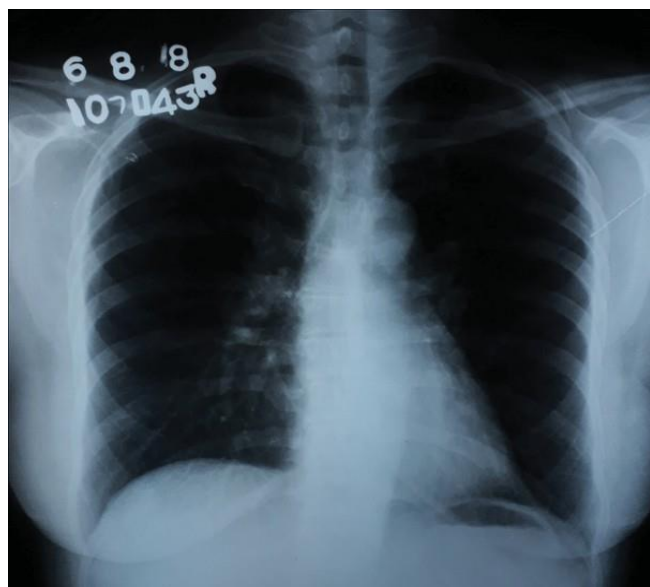


Figure 1: Chest X ray PA view showing bilateral hilar lymphadenopathy.

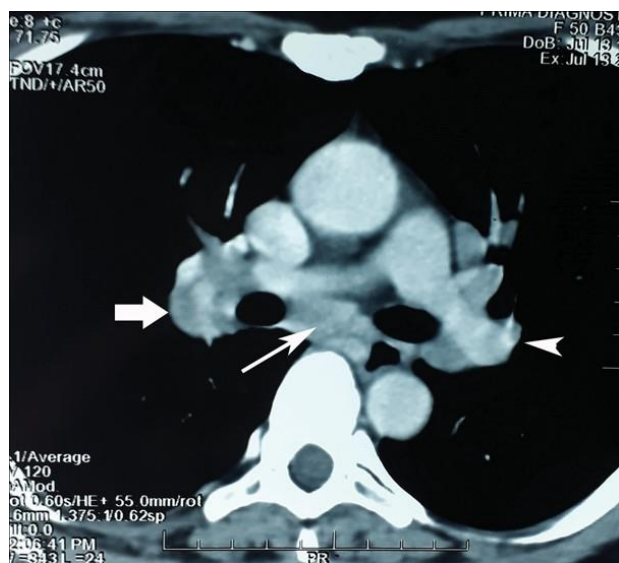


Figure 2: CT scan image of chest shows mediastinal lymph node enlargement (arrow head- left hilar, thick arrow- right hilar, thin arrow- subcarinal).

was commenced in left lower limb and soon involved the right lower limb, both proximally and distally. The weakness was progressive in severity and upper limbs were affected during next 2-3 days, albeit to a lesser degree than lower limbs. She also felt pain in her back around lower thoracic region before the onset of weakness. The initial weakness was later followed by numbness and generalized muscle pain. As the condition progresses, she developed left sided lower motor type VIIth cranial nerve palsy after about 1 week following the onset of limb weakness. However, there was no alteration of consciousness, convulsions, diplopia, visual disturbances, dysphagia or sphincter involvement. There were no similar episodes in the past. She denied history of acute gastroenteritis or respiratory tract infection prior to the onset of neurological symptoms. A neurological examination revealed bilateral symmetrical weakness with power grade 4/5, both proximally and distally with absent deep tendon reflexes. The upper limbs were

less affected compared to lower limbs. Apart from left sided facial weakness, the rest of the cranial nerves and cerebellar functions were within normal limits. There were no lymphadenopathy or skin rashes. The examinations of respiratory, cardiovascular and abdominal systems were clinically unremarkable. The Nerve Conduction Studies (NCS) done at this moment revealed demyelinating type polyneuropathy with normal electromyogram. She was immediately treated with intravenous immunoglobulin 0.4g/Kg/day for suspected GBS according to opinion from neurology specialists. She demonstrated improvement in facial and limb weakness with treatment, however developed a new onset lower motor neuron type VIIth cranial nerve palsy in right side at the end of five days treatment.

Cerebrospinal Fluid (CSF) analyzed after one week of symptom onset showed mild elevation of protein up to 80 mg/dL (20-40) and mild pleocytosis; 9 white cells with 100% lymphocytes (normal<5).

She was further evaluated for chronic lung disease. A bronchoscopic examination was normal. An EBUS examination found enlarged lymph nodes at 4L, 7 and 10R stations. Transbronchial aspiration showed benign inflammatory granulomas confirming the diagnosis of sarcoidosis. Bronchoalveolar lavage was negative for acid fast bacilli, MTB GeneXpert for tuberculosis, and fungal studies. However, it was not possible to perform differential white cell analysis. Furthermore, bone marrow examination, ultrasound scan of abdomen, HIV serology, antinuclear antibodies and rheumatoid factor were normal.

She was diagnosed with sarcoidosis with supportive investigations and treatment commenced with prednisolone 30 mg daily. She demonstrated a marked improvement of her neurological and respiratory symptoms. The repeat ACE levels and serum calcium levels were normalized with treatment further supporting the diagnosis of sarcoidosis. The repeat NCS done after 6 weeks of treatment demonstrated a significant improvement of demyelinating type polyneuropathy.

Discussion

Neurological manifestations may occur in 5%-20% of cases with sarcoidosis [3]. About half of patients with neurosarcoidosis have pre-existing systemic disease. However, neurological manifestations precede the diagnosis of sarcoidosis in up to 70% according to some reports [2,4,5]. In 10%-17% of cases with neurosarcoidosis, the disease is limited to nervous system [4]. Sarcoidosis can involve any part of the nervous system [3]. Cranial neuropathy is the commonest manifestation of neurosarcoidosis [2,5]. Though any cranial nerve may be affected, either in isolation or in combination, cranial nerve VII is most frequently involved. However, optic neuropathy seems to be commoner according to more recent studies [2].

Peripheral neuropathy occurs in up to 20% of neurosarcoidosis [1,2]. Symmetrical axonal type sensory motor polyneuropathy is the most common type of peripheral neuropathy [1]. Focal or multifocal mononeuropathy, polyradiculopathy, vascular neuropathy and demyelinating neuropathy are rarer forms of neurosarcoidosis [1]. The mechanism of sarcoid neuropathy is not well understood [2,3]. Compression of nerve fibers due to sarcoid granulomas or immune mechanism leading to axonal loss and demyelination are the main postulated theories [2]. In addition, vasculitis leading to ischemic nerve damage has been shown in some cases [2,6]. The clinical manifestations vary according to the type of neuropathy. Abnormalities of proprioception and vibration due to large nerve fiber involvement is frequently encountered. This form of neuropathy tends to follow an acute or subacute course, and associated with a good prognosis.

Neurosarcoidosis affecting small nerve fibers conducting pain, temperature and autonomic impulses occur rarely. Burning pain, paresthesia, restless leg syndrome, dry skin with reduced perspiration are the usual manifestations of this form of neuropathy, which generally have a chronic course with a poor outcome [1].

Demyelinating type of neuropathy due to sarcoidosis is rarely encountered. This pattern of neuropathy has been reported in acute, subacute or chronic forms. Singhal et al published a case of sarcoid neuropathy masquerading as CIDP over a decade [6]. Bayrouiti et al reported another case of CIDP in a pre-diagnosed case of sarcoidosis [7]. A case of neurosarcoidosis misdiagnosed as AIDP in a young female was reported by Rizk et al. [8].

Sarcoid neuropathy mimicking GBS have been reported in few cases. Neurological manifestations have been the presenting symptoms leading to diagnosis of sarcoidosis in some cases [9-12]. However in our patient neurological features developed following the onset of commonly presenting pulmonary manifestations. Ascending paralysis progressing to involve facial nerve palsy seen in some cases [9,10] as in our case.

Confident diagnosis of neurosarcoidosis as the cause of acute demyelinating neuropathy is challenging. Findik et al. stated that the presence of severe pain in lower back is suggestive of GBS rather than sarcoidosis [9]. A series of characteristics aiding the distinction of neurosarcoidosis from GBS was mentioned by Miller et al. Accordingly GBS has a wide range of age at presentation compared to sarcoidosis while having equal gender distribution [10]. Neuroelectrophysiological studies including nerve conduction tests and electromyogram show prolonged or absent F waves and H reflexes in demyelinating neuropathy. Sural nerve conduction is typically normal in GBS [13]. In our patient, F waves were delayed or absent, however sural nerve conduction was delayed too, suggesting the acute demyelination was due to sarcoidosis rather than GBS as the diagnosis.

Elevated CSF protein levels disproportionate to the cells, known as cytoprotein dissociation, is a well-recognized feature in GBS. However, CSF pleocytosis is observed in 40%-70% and elevated protein in 40%-73% of neurosarcoidosis with leptomeningeal involvement [2]. This pattern of CSF results was observed in our patient further suggesting acute sarcoid neuropathy as opposed to GBS. Other CSF findings include the presence of oligoclonal bands and elevated immunoglobulin G index. Presence of elevated CSF ACE levels is insensitive, but highly specific [2]. Nerve biopsy and examination for typical non caseating epithelioid granulomas can help to diagnose neurosarcoidosis. However, in some cases the demonstration of typical histological appearance in another affected organ has confirmed the diagnosis of sarcoidosis while carefully excluding the other possibilities for neuropathy [9-11].

It is extremely important for accurate distinction of neurosarcoidosis from GBS in patients presenting with acute neurological weakness to initiate proper treatment. Sarada et al described as case of GBS camouflaging neurosarcoidosis in a diagnosed patient with sarcoidosis demonstrating the difficulty of accurate demarcation among both conditions [14]. Various modalities of treatment for acute demyelinating type polyneuropathy due to sarcoidosis have been used in published cases. Steroids and plasma paresis has led to rapid improvement in some cases [11]. The cases more suggestive of GBS have been treated with IVIG [9,14]. Though limb weakness and unilateral facial weakness improved with Intravenous Immunoglobulin (IVIG), our patient developed new onset facial weakness in opposite side, which improved with high dose steroid.

Conclusion

Sarcoidosis is a multisystem inflammatory disease with diverse clinical manifestations. Peripheral neuropathy due to sarcoidosis occurs in several forms, including rare acute demyelinating subtype. Clinical features of sarcoid neuropathy can mimic GBS when occurs acutely. Clear distinction is important for initiation of appropriate therapy. Clinical, neurophysiological, histological features and CSF analysis may provide valuable clues for such distinction. Clinicians should consider sarcoid neuropathy as a differential diagnosis for GBS, especially in the presence of atypical feature. Similarly, efforts should be taken to identify true GBS cases when presenting with acute weakness in pre-existing sarcoidosis.

Consent

Written informed consent was obtained from the patient for publication of this case report and accompanying images. A copy of the written consent is available for review by the Editor-in-Chief of this journal.

Competing Interest

The authors declare that they have no competing interest.

Authors' Contribution

DM and SN made the clinical diagnosis and supervised the manuscript drafting. ARB, SS and SD drafted the first manuscript, reviewed the literature and involved in direct management of the patient. DM and SN supervised the manuscript drafting. All authors read and approved the final manuscript.

References

1. Hebel R, Dubaniewicz-Wybieralska M, Dubaniewicz A (2015) Overview of neurosarcoidosis:Recent advances. *J Neurol* 262:258-267.
2. Lacomis D (2011) Neurosarcoidosis. *Curr Neuroparmacol* 9: 429-436.
3. Dutra LA, Braga-Neto P, Oliveira RA, Pedrosa JL, Abrahao A, et al. (2012) Neurosarcoidosis: Guidance for the general neurologist. *Arq Neuropsiquiatr* 70: 293-299.
4. Iannuzzi MC, Rybicki BA, Teirstein AS (2007) Sarcoidosis. *N Engl J Med* 357: 2153-2165.
5. Hoyle JC, Jablonski C, Newton HB (2014) Neurosarcoidosis: Clinical review of a disorder with challenging inpatient presentations and diagnostic considerations. *Neurohospitalist* 4: 94-101.
6. Singhal NS, Irodenko VS, Margeta M, Layzer RB (2012) Sarcoid polyneuropathy masquerading as chronic inflammatory demyelinating polyneuropathy. *Muscle Nerve* 52: 664-668.
7. Mansour M, Souissi W, Beyrouiti R, Abouhassen A, Mrissa R (2017) Chronic demyelinating inflammatory polyradiculoneuropathy associated with sarcoidosis. *J Neurol Disord* 5: 328.
8. Rizk C, Savitt D, Jain S, Kass J (2016) A case of neurosarcoidosis masquerading as subacute inflammatory demyelinating polyneuropathy. *Neurology* 86: P3.371.
9. Findik S, Bulbul R, Ozbenli T, Aslan E, Sandikci U (2011) Sarcoidosis and Guillain- Barré syndrome. *Acta Neurol Belg* 111: 72-75.
10. Miller R, Sheron N, Semple S (1989) Sarcoidosis presenting with an acute Guillain-Barre syndrome. *Postgrad Med J* 65: 765-767.
11. Bhat R, Ahad R, Ahmed I, Lee G, Khosla S (2016) Neurosarcoidosis presenting as acute inflammatory polyneuropathy. *Neurology* 86: P6.142.
12. Fahoum F, Drory V, Issakov J, Neufeld M (2009) Neurosarcoidosis presenting as Guillain- Barré-Like syndrome. A case report and review of the literature. *J Clin Neuromuscul Dis* 11: 35-43.
13. Wee AS, Abernathy SD (2003) The sural sensory nerve is usually spared in Guillain-Barre syndrome. *J Miss State Med Assoc* 44: 251-255.
14. Sarada PP, Sundararajan K (2016) The devil is in the detail: Acute Guillain-Barré syndrome camouflaged as neurosarcoidosis in a critically ill patient admitted to an Intensive Care Unit. *Indian J Crit Care Med* 20: 238-241.