

## Extra-Digital Glomus Tumor of the Ankle in a Toddler: A Rare Case with Unusual Presentation

Sadaf Haiyat\*, Kafil Akhtar, Feroz Alam and Anam Siddiqui

Department of Pathology, Jawaharlal Nehru Medical College, Aligarh Muslim University, India

\*Corresponding author: Haiyat S, Department of Pathology, Jawaharlal Nehru Medical College, Aligarh Muslim University, India, E-mail: sadafhayat143@gmail.com

Received: Apr 06 2024, Accepted: May 25 2024; Published: May 29, 2024, DOI: 10.59462/jpdm.1.1.104

Citation: Haiyat S, Akhtar K, Alam F, Siddiqui A (2024) Extra-Digital Glomus Tumor of the Ankle in a Toddler: A Rare Case with Unusual Presentation. Journal of Pathology and Diagnostic Microbiology. 1(1):104

Copyright: © 2024 Haiyat S, et al. This is an open-access article distributed under the terms of the Creative Commons Attribution License, which permits unrestricted use, distribution, and reproduction in any medium, provided the original author and source are credited.

### Abstract

Glomus tumours are rare mesenchymal neoplasms arising from glomus bodies in the skin. Extra digital glomus tumours are often misdiagnosed owing to their non-specific clinical presentations and unusual locations. An extensive search revealed not a single case of solitary glomus tumours of ankle in a toddler. We present here a unique case of an extradigital glomus tumour in a 15 month old male child with swelling in the right ankle for the last 6 months. Histopathology examination and immunohistochemical studies confirmed the diagnosis of glomangioma (a form of glomus tumour). The patient was followed for one year after complete excision of the tumour, with no evidence of local recurrence or metastasis till date.

**Keywords:** Extradigital glomus tumour; Immunohistochemistry; Toddler

### Introduction

Glomus Tumours (GT) are rare mesenchymal neoplasms, comprising about 1.6% of all soft-tissue tumours [1]. They are benign tumours composed of cells resembling modified smooth muscle cells, representing a neoplastic component of the perivascular glomus body. They usually arise from neuro-myo-arterial glomus, an arterio-venous anastomosis which helps in the thermoregulation of skin by arteriovenous shunting of blood [2,3]. These tumours appear as solitary or multiple tumours and often present as bluish discoloration or nodules accompanied by the classic triad of pain, cold sensitivity and point tenderness [2].

The average age of presentation ranges from 20 to 40 years, although these tumours can occur at any age. [3] The majority of the glomus tumours occur in the distal extremities particularly sub-ungual regions of the digits, deep dermis of the palm, wrist, forearm, and foot. Glomus tumours have been identified in extra digital sites including the bone, tongue, stomach, rectum, mesentery, lung, mediastinum, sacrum, coccyx, and the head and neck [4].

These tumours often pose diagnostic dilemmas, as they clinically mimic haemangiomas and venous malformations so their actual prevalence is difficult to ascertain. After extensive research of literature, we could not find a single case report of glomus tumour of the ankle in a toddler till date. We hereby describe a rare case report of extra digital glomus tumour of the ankle in a 15 month toddler.

### Case Report

A 15 month toddler was brought to the paediatric surgery outpatient clinic with a history of swelling on the left ankle since 6 months. The child was afebrile without any complaints of pain and limitation of movement. There was no history of preceding trauma nor significant past medical or surgical history of significance. On local examination, the swelling was around 3 × 2 cm in size, bluish-purple in

colour with normal surrounding area (Figure 1). The swelling was soft in consistency, non-tender, mobile and compressible. Regional lymph nodes were not enlarged. Systemic examination was normal. On the basis of above findings, a provisional clinical diagnosis of haemangioma was made.

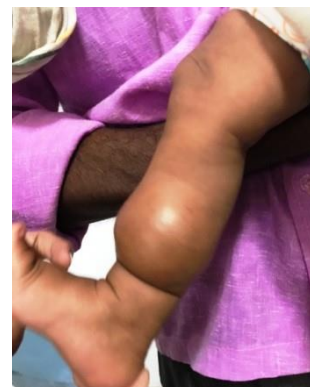

Figure 1: Clinical photograph shows a fusiform swelling at the distal end of left leg involving ankle.

Routine blood investigations including complete blood count, erythrocyte sedimentation rate, and liver and renal function tests were within normal limits. Plain films of the affected foot did not reveal any abnormality. MRI of the affected foot was planned but the patient could not afford the cost of this investigation. Patient was referred to the paediatric surgery unit where the lesion was excised and was subsequently sent for histopathological evaluation.

Gross examination of the specimen revealed a single round greyish brown mass measuring 2.5 × 1.5 × 1 cm. Microscopic examination revealed a well circumscribed lesion with branching vasculature having perivascular arrangement of sheets of tumour cells (Figures 2a and 2b).

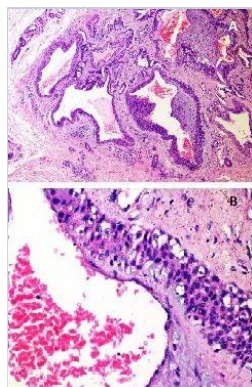


Figure 2: (A) Section shows dilated vasculature having perivascular arrangement of tumour cells. (H&E, 10X); (B) Ue tumour cells have round to oval nuclei with indistinct borders and eosinophilic cytoplasm. (H&E, 40X).

Ue tumour cells were round, relatively uniform in size with indistinct cell borders, centrally placed nucleus and moderate amount of eosinophilic cytoplasm without any evidence of nuclear atypia, necrosis or haemorrhage. Foci of epithelioid cells with moderate amount of clear to eosinophilic cytoplasm and round nuclei with fine chromatin were also seen.

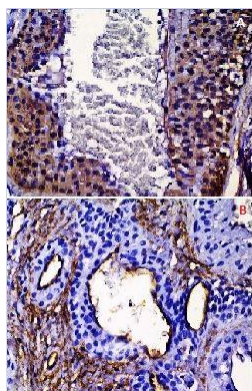


Figure 3: (A) Neoplastic cells exhibits strong cytoplasmic smooth muscle actin expression (immunoperoxidase, 40X); (B) Positive staining of CD34 in endothelial cells, however negative in glomus cells.

A provisional diagnosis of glomus tumour was given. Ue tumour cells showed immunoreactivity for Smooth Muscle Actin (SMA) (Figures 3a and 3b) but were negative for CD34 and CD31; thus ruling out haemangioma and hemangiopericytoma. Based on above findings, a final pathologic diagnosis of angiomatous type of glomus tumour was reported.

## Discussion

Glomus Tumour (GT) is a benign vascular tumour derived from the deformed smooth muscle cells of the glomus body, first described by Masson in 1924 [5]. Uese tumours are composed of endothelium-

lined vascular spaces (the Sucquet-Hoyer canal) surrounded by glomus cells [6,7]. Ue glomus body is a specialized form of arteriovenous anastomosis involved in temperature regulation. Ue initiating event for glomus cell proliferation is unknown. Some authors have postulated that trauma induces solitary sub-ungual glomus tumours, although this theory is not well studied [8].

Glomus tumours are of two types: solitary and multiple, the latter is further sub-divided into regional or disseminated. Solitary GT is usually seen in adults and found equally in both sexes. Uere is a slight female preponderance of sub-ungual glomus tumours [9]. Ue commonest site is the hand, particularly the sub-ungual part of digits. Other sites include palm, wrist, forearm, foot and tip of the spine. Rarely, the tumour may occur in the gastrointestinal tract (stomach, small intestine and colon), trachea, lungs, mesentery, bone, vagina and the cervix [10]. In our patient, the site involved was ankle which is a rare occurrence. Aler extensive review of literature, we could not find a single case report of glomus tumour of ankle in a toddler.

Glomus tumours commonly present with a classic triad of severe pain, point tenderness and cold sensitivity. Other clinical features include blue discoloration, palpable nodule and nail deformity in sub-ungual tumours. Glomus tumours are typically composed of 3 components: glomus cells, vasculature, and smooth muscle cells. Uey may be subcategorized as solid glomus tumour (with poor vasculature and scant smooth muscle component) glomangioma (with prominent vascular component) or glomangiomyoma (with prominent vascular and smooth muscle components). Solid glomus tumour is the most common variant (75%) followed by glomangioma (20%) and glomangiomyoma (5%) [11]. Ue histopathology in our case showed predominantly vascular component, supporting the diagnosis of glomangioma.

A di9erential diagnosis of glomus tumour includes carcinoid tumour, hemangiopericytoma, sclerosing haemangioma, leiomyoma and paraganglioma. Carcinoids are olen confused with glomus tumours because of similar morphology. Although by immunostaining they show positive immunoreactivity for cytokeratin, chromogranin A and synaptophysin [10]. Sclerosing haemangiomas are positive for TTF-1, surfactant apoprotein A and cytokeratin. Paragangliomas are typically composed of round epithelioid cells with small nuclei and express neuroendocrine markers and S-100 protein. Smooth muscle neoplasms comprise spindle cells with a fascicular pattern and express smooth muscle markers like alpha smooth muscle actin and h-caldesmon. Ue di9use CD34 staining pattern in hemangiopericytomas is instrumental in di9erentiating them from glomus tumours. However in our case the glomus cells exhibited strong positivity for alpha SMA and was negative for CD34 and CD3, thus ruling out haemangioma and haemangiopericytoma.

A complete extirpation is the treatment of choice in childhood glomus tumours to relieve pain and prevent recurrences [2,12,13]. Ue incidence of tumour recurrence aler surgical excision ranges from 5% to 50% depending primarily on the surgical technique [13]. Total extirpation was performed aler careful avulsion of the surrounding tissues of the tumour in our patient. Uere was no evidence of recurrence or metastasis on follow-up aler 1 year of treatment.

## Conclusion

We report an extremely rare case of an extra digital glomus tumour arising in the subcutaneous tissue of ankle in the toddler. Ue physicians must include glomus tumours in the di9erentials of extra

---

digital lesions, especially in unusual locations so that early diagnosis and treatment could be rendered to the patients.

### Acknowledgement

Sadaf Haiyat performed the research and wrote the paper, Feroz Alam designed the research study, Anam Siddiqui contributed essential reagents or tools & Kafil Akhtar analysed the data

### Financial Support and Sponsorship

We haven't received any kind of financial support or sponsorship.

### Conflict of Interest

There are no conflicts of interest.

### References

1. Shugart RR, Soule EH, Johnson EW (1963) Glomus tumour. Surg Gynecol Obstet 11: 334-340.
2. Lee DW, Yang JH, Chang S, Won CH, Lee MW, et al. (2011) Clinical and pathological characteristics of extradigital and digital glomus tumours: a retrospective comparative study. J Eur Acad Dermatol Venereol 25: 1392-1397.
3. Weiss SW, Goldblum JR (2007) Perivascular tumours in Enzinger and Weiss's Soft tissue tumours. Mosby 5th Edition 751-756.
4. Kale SS, Rao VK, Bentz ML (2006) Glomus tumour of the index finger. J Craniofac Surg 17: 801-804.
5. Masson P (1924) Le glomus neuro-myo-arteriel des regions tactiles et ses tumeurs. Lyon Chi 21: 257-280
6. Chatterjee JS, Youssef AH, Brown RM, Nishikawa H (2005) Congenital nodular multiple glomangioma: a case report. J Clin Pathol 58: 102-103.
7. Rohrich RJ, Hochstein LM, Millwee RH (1994) Subungual glomus tumours: an algorithmic approach. Ann Plast Surg 33: 300-304.
8. Sajad AS, Ajaz R, Arshad BK (2010) Subungual glomus tumour-a case report. J Pakistan Assoc Dermatol 20: 42-44.
9. Miettinen M, Paal E, Lasota J, Sobin LH (2002) Gastrointestinal glomus tumours: a clinicopathologic, immunohistochemical, and molecular genetics study of 32 cases. Am J Surg Pathol 26: 301-311.
10. Dawber RP, Baran R (1992) Disorders of nails. In: Champion RH, Burton JL, Ebling FJG, editors. Rook/Wilkinson/Ebling Textbook of Dermatology. 5th edition, Oxford: Blackwell Sci 2497-2532.
11. Yasushi A, Hirotaka K, Masahiro H, Takuo S, Kouji A, et al. (2012) A Primary Pulmonary Glomus Tumour: A Case Report and Review of the Literature. Case Rep Pathol.
12. Vasisht B, Watson HK, Joseph E (2004) Digital glomus tumours: a 29-year experience with a lateral subperiosteal approach. Plast Reconstr Surg 114: 1486-1489.
13. Van Geertruyden J, Lorea P, Goldschmidt D, de Fontaine S, Schuind F, et al. (1996) Glomus tumours of the hand: a retrospective study of 51 cases. J Hand Surg Br 21: 257-260.