

Low-Pain Dressing Change Faster Healing of the Wound

Introduction

Dressing changes for chronic wounds are associated with high levels of physical and psychological stress for the patient. The nurse's primary responsibility is to minimize the stress factors associated with dressing changes or to manage them professionally. The article will focus on the pathophysiology of the wounds and the choice of dressing material. Using the examples of wounds in Pyoderma gangraenosum (PG), Livedo-Vasculopathy (LV) and Caliphyllaxis (CP), which are extremely painful at the onset of the disease, I would like to demonstrate ways of minimizing pain in wounds based on the pathophysiology of the wounds.

Aim:

- Causes of severe pain in PG, LV and CP wounds
- Choice of dressing material
- Special procedures for carrying out dressing changes for the mentioned diseases

The primary objective is to minimize discomfort during wound care procedures. In 2020, the International Association for the Study of Pain (IASP) revised its 1979 definition of pain. While pain perception is a multifaceted phenomenon, understanding the pathophysiological origins of wounds can offer valuable insights into how to perform a low-pain dressing change. A general overview of low-pain dressing changes can be found at the Wundzentrum Hamburg.

Pyoderma gangraenosum (PG) (Figure 1) is an autoinflammatory dermatosis that causes mostly solitary, painful, and large ulcers. Pyoderma gangraenosum (PG) is an autoinflammatory dermatosis that causes mostly solitary, painful, and large ulcers. It can be associated with an underlying systemic disease. Autoinflammation refers to the induction of sterile inflammation without circulating autoantibodies or autoreactive T cells." (Kompendium Wikiderm) Ulcerations can develop within days or even hours. An interplay of neutrophil dysfunction, cytokine

Editorial Article

Tina Rohl*

Department of Dermatology, University Hospital Hamburg-Eppendorf, Hamburg, Germany

***Correspondence:** Tina Rohl, Department of Dermatology, University Hospital Hamburg-Eppendorf, Hamburg, Germany, E-mail: t.roehl@uke.de

Received: 27 February 2024; **Processed:** 10 March 2024; **Accepted:** 22 March 2024

Copyright: © 2024 Rohl T. This is an open-access article distributed under the terms of the Creative Commons Attribution License, which permits unrestricted use, distribution, and reproduction in any medium, provided the original author and source are credited.

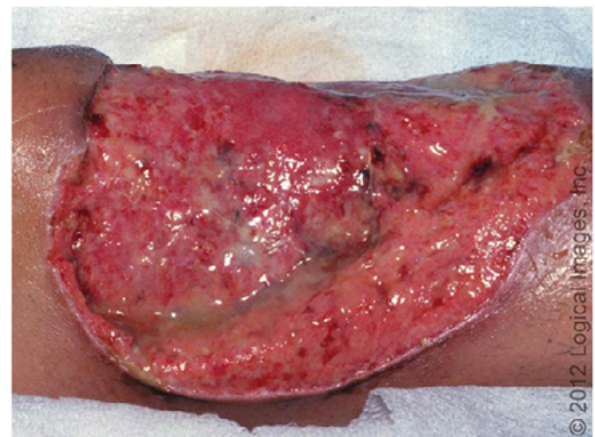

Figure 1. Pyoderma Gangraenosum

dysregulation and genetic predisposition is suggested. It is not a primary vasculitis since the inflammatory process is not directed primarily against the vessel walls.

The erythematous nodules or sterile pustules appear suddenly and may result from the slightest skin irritation: such as subcutaneous injection, insect bites, surgery, tight clothing, or the application or removal of a band-aid too quickly etc. This occurrence of a disease-specific skin change caused by a non-specific stimulus is also

known as the pathergy phenomenon. The ulcerations are progressive in size. Especially in the early stages of the disease, the reddened, raised, extremely painful wound edge is noticeable, which is usually also undermined.

The intense pain in PG is caused by sterile inflammation induced by inflammatory mediators. This inflammation leads to a persistent irritation of the skin's nociceptors, which are A γ fibers and C fibers. (Among other things the balance between activating and inhibiting substances determines the resting state of a nociceptive nerve. This results in peripheral sensitization of the nociceptors and increased pain, known as primary hyperalgesia. Patients complain of constant pain!

The pain is further intensified by the subsequent spinal sensitization in the dorsal horn neurons of the spinal cord (=secondary hyperalgesia): This results in

- That even the lightest touch is perceived as excruciatingly painful (allodynia), e.g. when wound irrigation solution is applied to the wound during wound cleansing,
- That the area around the wound is also perceived as painful.
- That mechanical stimuli that are otherwise tolerated, e.g. mechanical cleansing of a wound with a sterile compress, are also described as no longer tolerable. (Painful stimuli are perceived to be extremely intense).

Note: Extremely severe pain, particularly at the ulcer's edge, is caused by rapidly progressing sterile inflammation that irritates cutaneous pain receptors.

Livedo vasculopathy (LV): It is (Figure 2.1) also known as idiopathic atrophy blanche, is a skin condition characterized by a distinct appearance (Figure 2.1). It should be noted that the term 'atrophy blanche' is also used to describe star-shaped scars in cases of chronic venous insufficiency (CVI) on the lower leg. LV is typically found on the thighs and gluteal region. The predilection sites for ulcers are the ankles and the back of the foot on both sides, as there are fewer thrombolytic factors due to the lower temperature and greater perfusion pressure on the lower extremities so ulcer formation is favored.

The cause of these changes is a disturbance of the microcirculation in the small veins of the upper dermis with

recurrent venous thrombus formation with stasis, cyanosis and the consecutive accumulation of damaging metabolic metabolites. Additionally, reduced oxygen and nutrient supply to the tissue ultimately leads to skin ulcerations, also known as 'skin infarcts'.

Note: Extreme pain of the ulcerations due to irritation of pain receptors by accumulated metabolic products, ischemia and the pressure from resulting edema.

Calziphylaxis (CV) (Figure 3) is a multifactorial disease of renal or non-renal origin., (cirrhosis of the liver, Crohn's disease, tumor patients undergoing chemotherapy or rheumatoid arthritis.) It is associated with a disorder of calcium-phosphate metabolism, and it particularly affects the lower limbs. Intimal hypertrophy, calcification of the media of small and medium-sized cutaneous

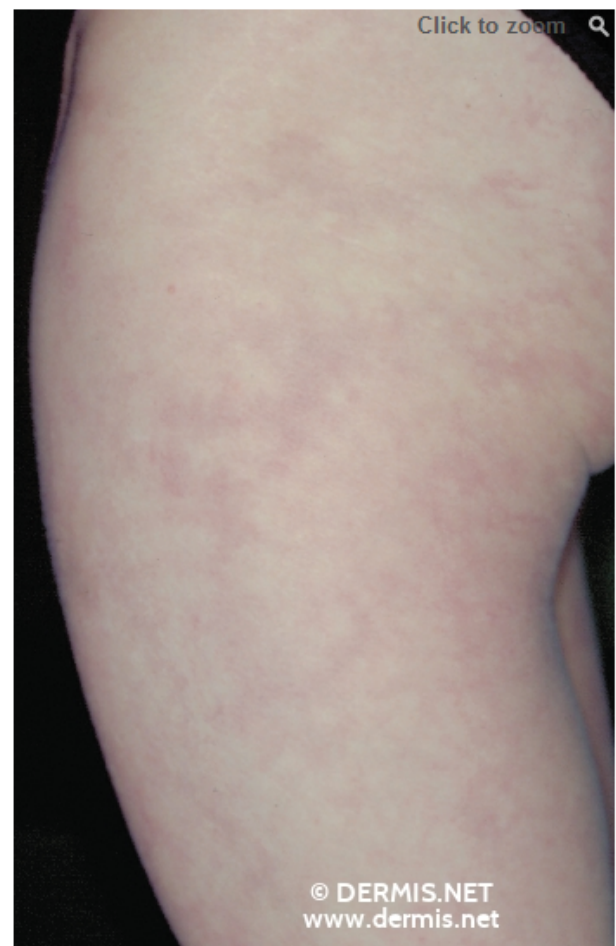


Figure 2. Livedo racemosa, at the beginning of the disease with lightning-like, open segments. In contrast to livedo reticularis: Reticular erythema with closed circular segments.

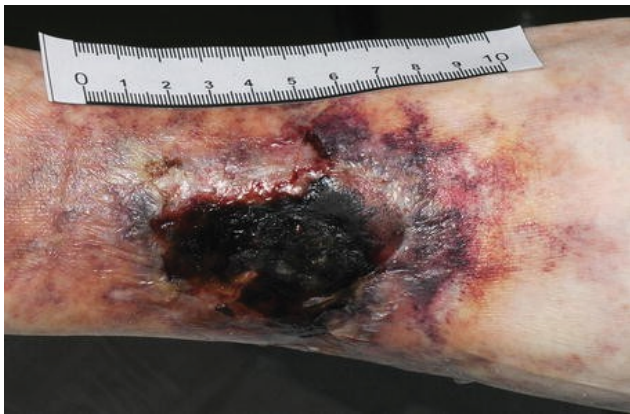

Figure 3.

vessels, secondary thrombosis, and increased activity of metalloproteinases in the skin and vascular walls cause ischemia, which are responsible for the severe pain of the ulcers. Additionally, the lamina muscularis of the vessel walls is remodeled into osteoblast-like cells, resulting in the formation of an extracellular bone matrix. This process reduces the flexibility of the vessel walls and exacerbates ischemia.

Neuropathic pain can also occur in all diseases mentioned above, making the pain complex and unpredictable. In which way degeneration and regeneration of the intraepithelial fibers, the increased expression of certain receptors on the nociceptors (e.g., the capsaicin receptor TRP V1) or the dysfunction of the vasa vasorum (due to the lack of NO there is permanent vasoconstriction of the vessels supplying the nerves) are causal factors of these diseases, has not been conclusively clarified yet.

A complication that also may arise is secondary infection of the wounds, which can cause additional pain and increase the risk of sepsis. To avoid this, it is important to clean the wounds properly. For the wounds mentioned above, a particularly careful and painless dressing change is recommended.

Low-pain dressing changes: How to perform

Basic measures

- Creating a stress-free environment. Position the patient comfortably according to their instructions. Send anyone who does not belong in the room out of the room. If

desired, offer music or TV and provide headphones. If the patient declines to observe the dressing change, this should be considered when scheduling the procedure.

- Inform the patient individually about the procedure, but avoid excessive demands. Involve the patient in the procedure if they wish.
- Prior to the procedure, reassure the patient that the dressing change can be paused at any point if the pain becomes too intense.
- Administer analgesia using either systemic and/or topical agents (see below).
- Close the windows.
- Ensure that the wound area is easily accessible.
- Ensure all necessary materials are available and properly set up, including large waste containers.

Practical organization of dressing materials

- Preparation of the workplace and materials should strictly adhere to hygiene rules to avoid infections, which can cause or increase pain. This also applies to the actual performance of the wound dressing change without touching the wound (known as “**non-touch-Method**”).
- It is important to select atraumatic dressing materials (Table 1) that are without adhesive and, if possible, have an anti-adhesive surface (e.g. silicone).
- If daily wound dressing changes are necessary, overlapping wound edge spacers can be advantageous when combined with a superabsorber. These dressings maintain wound warmth, protect against further trauma, provide low-pressure wound coverage, and enable effective exudate management. The use of a hydrogel should be determined based on the wound's condition. Additionally, a morphine hydrogel that can remain in the wound for 24 hours may be considered. Superabsorbent dressings can be secured without pressure using a gauze bandage.
- The wounds at the onset of PG, LV and CV are typically a few millimeters deep, shallow, and have little to moderate exudation. Over time, they can become very

	Material	To avoid
Wound edge protection	Breathable Acrylat-Terpolymerfilme Use in case of massive exudation: LV-Paste (Locacorten-Vioformpaste)	CAVE: After use, it is impossible to assess the wound environment. Additionally, it is not suitable for PG.
Wound cleansing	NaCl 0,9% oder Ringer-Lösung (pleasant temperature) For infection treatment: Octenidin mit Phenoxyethanol	Polihexanide is rather impractical because of the long exposure time of 10-20 minutes, the wounds cool down, which can cause further pain, dry out and also become contaminated.
Primary wound dressing	Active substance-free spacer grids, preferably non-adhesive silicone grids Self-adhesive wound contact dressings Hydrogel, if ist necessary Alginate is also a good possibility Hydroactive wound dressing with Ringer's solution and polyacrylate (SAP) To support hydrolytic debridement: transparent gel dressing made of absorbent polyurethane polymers	Not always at PG
Secondary wound dressing	Non-adhesive foam dressings are possible Non-adhesive foam dressings containing an analgesic Superabsorber or absorbent pads	Foam dressings with adhesive edge No simple compresses
For Fixing	Wide gauze bandages	
Kompression Bei der LV und CP möglich	Only after a strict indication check and then only with Lite multi-component systems	For PG only if the wounds are healing, otherwise it's too painful.

large, making spacer meshes and possibly hydrogels suitable as primary wound dressings. In the case of PG, hydroactive wound dressings with Ringer's solution and polyacrylate (SAP) can also be tried.

Special measures when changing dressings on the mentioned wounds

- Before removing the old dressing, soak it with NaCl 0.9% or Ringer's solution for approximately 30 minutes before the VW, if necessary. This step is not required when using spacer meshes, as the absorbent dressings or superabsorbents can be removed from the wound area without causing pain.
- The selection of wound cleansing method should be based on the cause of the wound and its environment.
- It may be necessary to apply a local anesthetic cream to the wound approximately 60 minutes before cleansing and cover it with a semi-permeable film. -In some cases, a morphine spray or morphine hydrogel can be applied to the wound (LV, CP) or specifically to the wound edge (PG).
- The patient should be given the option to warm the cleansing solution.
- To clean the wound, pour the wound irrigation solution

or wound antiseptic over the wound and carefully pull it over the wound with a soaked compress held by tweezers (LV, CP). It is important to avoid touching the wound edge during dressing changes. When performing irrigation with a syringe, it should be done without applying pressure.

- Surgical debridement is rarely performed in cases of LV and almost never in PG, as disease progression is expected.
- The use of a curette for debridement in CP should also be viewed with great skepticism, as extreme wound healing disorders are expected in all ulcerations due to the disparate condition of the vessels. Even gentle mechanical debridement must be carried out with particular care.
- Hydrolytic debridement can be achieved using polyacrylate activated with Ringer's solution, in addition to hydrogel and morphine gel.

Wound edge protection

- In the case of PG, it is important to maintain a distance of at least 2 mm from the wound edge to prevent pain and progression. The wound edge protection lollipops have been found to be highly effective. Sprays are too imprecise, and ointments or creams can hinder proper assessment of the wound area.
- The primary and secondary dressings should be applied using forceps, and the secondary dressings should be fixed with a gauze bandage without tension. This can be

referred to as a modeling dressing. Fixation bandages should be as wide as possible to achieve optimal low-pressure distribution, particularly for PG wounds.

Conclusion

Dressing changes must be performed with minimal or no pain. It is important to consider the complete origin of pain, as defined by the International Association for the Study of Pain (IASP). The dermatological diseases mentioned above can cause painful wounds with both nociceptive and neuropathic origins. These wounds can result in either an extremely painful wound surface (LV, CP) or a particularly painful wound margin (PG). Therefore, when selecting the dressing material and performing the wound dressing, special consideration must be given.

To achieve pain relief in LV, moderate low multicomponent compression can be applied after the VW to prevent thrombosis and relieve the ischemic pain caused by the existing edema. This approach can be based on PAD without critical ischemia and a CADI between 0.5-0.9. In cases of CP, where ischemic pain is caused by pathological changes in the arteries and the formation of collateral circulation does not provide adequate tissue supply, it is important to select a wound dressing that allows for low pressure fixation. Mild compression may be attempted if necessary. When managing wounds, it is important to consider the causes of pain in the treated diseases. With consistent systemic therapy and professional, low-pain wound management, even these wounds can often heal successfully [1-20].

References

1. Dissemond, Joachim. "Blickdiagnose chronischer Wunden." *Aufl Viavital, Köln* (2012).
2. Mutschler, Ernst, Gerd Geisslinger, Heyo K. Kroemer and M. Schäfer-Korting. "Mutschler Arzneimittelwirkungen." *Pharmakologie und Toxikologie* 9 (2001).
3. Panfil, Eva-Maria and Gerhard Schroder. "*Pflege von Menschen mit Chronischen Wunden*." Hogrefe Verlag, 2015.
4. Bultemann, Anke, Harald Daum and Werner Sellmer, eds. "*Wundfibel: Wunden versorgen, behandeln, heilen*." Medizinisch Wissenschaftliche Verlagsgesellschaft, 2018.
5. Duchting, Andrea. "Verzögerte Aktivierungskinetiken von TH2 und TH17 Zellen im Vergleich zu TH1 Zellen." PhD diss., Friedrich-Alexander-Universität Erlangen-Nürnberg (FAU), 2020.
6. Bircher, Andreas J., Lorenzo Pelloni, Isabella Terrani and David Spoerl, et al. "Therapeutische Umschau 79 (2022): 238-246.

7. Gerjol, Bastian P., Sandra Schuh and Julia Welzel. "Pyoderma gangraenosum—wenn Inflammation ulzeriert." (2021).
8. Dissemond, Joachim. "Kurzübersicht der Diagnostik des Pyoderma gangraenosum." *Zeitschrift für Rheumatologie* 10 (2018): 857-859.
9. Sturmer, E. K. and M. Storck. "Choosing wisely together—Recommendations on the treatment of chronic wounds." *Gefäßchirurgie* 26 (2021): 164-174.
10. Dissemond, Joachim, Angelo V. Marzano, Philip J. Hampton and Alex G. Ortega-Loayza. "Pyoderma Gangrenosum: Treatment options." *Drugs* 83 (2023): 1255-1267.
11. Dissemond, Joachim. "Modern management of chronic wounds." *Der Hautarzt* 72 (2021): 733-744.
12. Dissemond, J., S. Läuchli, H. Partsch and M. Stücker, et al. "Praxisrelevante Aspekte der Kompressionstherapie für Patienten mit chronischem Ulcus cruris unter besonderer Berücksichtigung der Wirtschaftlichkeit." *WundManagement. 2018b* 12 (2021): 77-84.
13. Jockenhoefer, F. and J. Dissemond. "Pyoderma gangraenosum from the right diagnostic investigations to targeted therapy." *Phlebologie* 45 (2016): 333-340.
14. Ketteler, Markus, Georg Schlieper and Jurgen Floege. "Calcification and cardiovascular health: New insights into an old phenomenon." *Hypertension* 47 (2006): 1027-1034.
15. Pfeifer, J., H. Sairawan, M. Wegener and S. Philippou, et al. "An unusually painful leg ulcer in an 81-year-old patient: An interdisciplinary challenge." *Der Internist* 62 (2021): 424-432.
16. Protz, Kerstin. "Verbandwechsel: Was bewirkt Patientenedukation?." *Heilberufe* 69 (2017): 20-23.
17. Skowronsky, A. and C. von Reibnitz. "Wundversorgung von A–Z." In *Wundversorgung von A–Z*, pp. 45-151. Berlin, Heidelberg: Springer Berlin Heidelberg, 2017.
18. Kolbig, Norbert, Gerhard Schröder and Kerstin Protz. "Pflege Kolleg 21 Wunde und Umgebung." *ProCare* 27, no. 3 (2022): 29-39.
19. Protz, Kerstin. "MARSI-wenn Verbandmittel kleben." *Heilberufe* 73 (2021): 16-18.
20. Schurmann, Norbert. "Behandlung exulzierender Karzinome eine Herausforderung." *Schmerzmedizin* 34 (2018): 47-49.
21. Birklein, Frank and Benedikt Schoser. "Ursachen, Diagnostik und Therapieoptionen Claudia Sommer, Christian Geber, Peter Young, Raimund Forst."

Citation: Rohl, Tina. "Low-Pain Dressing Change Faster Healing of the Wound." *J Health Adv Nur* (2024): 110. DOI: [10.59462/3068-1758.2.1.110](https://doi.org/10.59462/3068-1758.2.1.110).