

Ocular Ischemic Syndrome: A Comprehensive Overview

Taoufik Abdellaoui*, Imane Tarib, Salem Joumany, Rachid Zerrouk, Karim Reda and Abdelbarre Oubaaz

Department of Ophthalmology, Military teaching hospital Med-V, Rabat, Morocco

*Corresponding author: Taoufik Abdellaoui, Department of Ophthalmology, Military teaching hospital Med-V, Rabat, Morocco, Tel: +212 639234211; E-mail: rowman_xrd@hotmail.com

Received: Jul 02 2024, Accepted: Aug 20 2024; Published: Aug 22, 2024, DOI: 10.59462/jedt.1.2.107

Citation: Abdellaoui T, Tarib I, Joumany S, Zerrouk R, Reda K, et al. (2024) Ocular Ischemic Syndrome: A Comprehensive Overview. Journal of Eye Disorders and Therapy, 1(2):107.

Copyright: ©2024 Abdellaoui T, et al. This is an open-access article distributed under the terms of the Creative Commons Attribution License, which permits unrestricted use, distribution, and reproduction in any medium, provided the original author and source are credited.

Abstract

Ocular ischaemic syndrome (OIS) is a severe form of chronic ischaemia of both anterior and posterior segments of the eye as well other orbital structures supplied by the ophthalmic artery. It is thought to be due to chronic hypoperfusion when carotid artery stenosis is greater than 90%. It typically affects patients during seventh decade or more, and it is usually associated with diabetes, heart and cerebrovascular disease. In rare cases, OIS may represent the first manifestation of a life-threatening carotid artery stenosis. This disease is often undiagnosed because it remains asymptomatic for a long period of time and has non-specific ocular manifestations.

Keywords: Ischaemic syndrome; Carotid stenosis; Atherosclerosis; Neovascularization

Introduction

Ocular ischaemic syndrome (OIS) is a severe form of chronic ischaemia of both anterior and posterior segments of the eye as well other orbital structures supplied by the ophthalmic artery. It is thought to be due to chronic hypoperfusion when carotid artery stenosis is greater than 90%. It typically affects patients during seventh decade or more, and it is usually associated with diabetes, heart and cerebrovascular disease. In rare cases, OIS may represent the first manifestation of a life-threatening carotid artery stenosis. We report a case of a 62-year-old patient, who presented an ocular ischaemic syndrome due to atheromatous occlusion of the ophthalmic artery [1].

Case Report

62-year-old patient, followed for high blood pressure during 10 years, presented for 3 months, a progressive decrease in visual acuity of his right eye.

At examination, right eye vision was no perception of light. Cornea was clear, there was an important episcleral venous dilatation, mid-dilated non-reactive pupil with uveal ectropion, important iris rubeosis and total cataract (Figure 1). Anterior chamber was shallow with angle neovascularization on gonioscopy. However, intraocular pressure was 10 mmHg. Posterior segment not visualized on ophthalmoscopy, but was normal on ophthalmic B-scan ultrasonography. Ue contralateral eye examination found no abnormalities. All these signs make of this case a typical clinical presentation of ocular ischaemic syndrome. Doppler ultrasound showed 85% carotid artery stenosis in the right side, and 60% at the left one.

Discussion

Ocular ischaemic syndrome is an uncommon condition which is the result of chronic hypoperfusion secondary to ipsilateral atherosclerotic carotid stenosis more than 90% resulting in 50% reduction of ipsilateral perfusion pressure [2]. It typically affects patients during

seventh decade and usually associated with diabetes, heart and cerebrovascular disease.

Symptoms of carotid artery disease frequently present to ophthalmologists. Though these may be sight threatening, they may represent the first signs of life-threatening carotid artery stenosis. These include cerebral transient ischaemic attacks, transient monocular blindness (amaurosis fugax), central or branch retinal artery occlusion, hypotensive retinopathy, and ocular ischaemic syndrome [3]. Of these associations with carotid artery disease, OIS presents the most challenging condition for the ophthalmologist

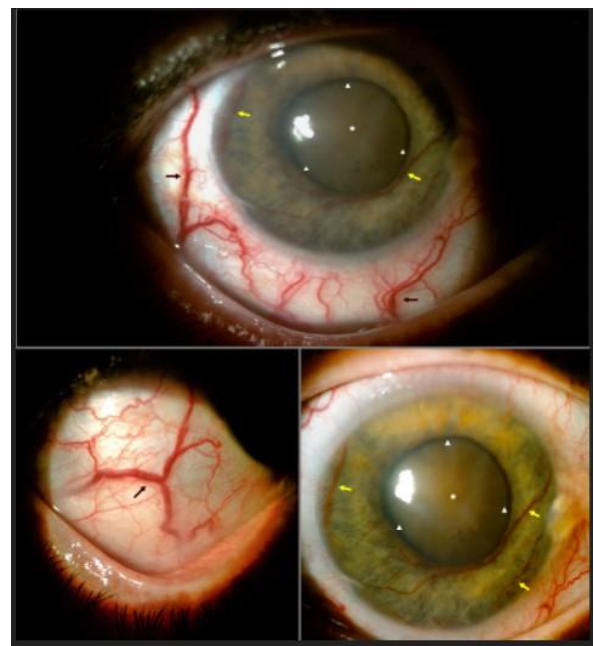


Figure 1: Photography of the anterior segment showing important episcleral venous dilatation (black arrows), iris rubeosis (yellow arrows), uveal ectropion (arrowheads), and total cataract (asterisk).

Ue ocular ischemic syndrome is unilateral is 80% of cases and affects both anterior and posterior segments. It presents usually with gradual vision loss over several weeks and occasionally with amaurosis fugax. In anterior segment examination we can observe diffuse episcleral injection, iris atrophy with rubeosis iridis which often progresses to neovascular glaucoma. Cataract is developed in advanced cases. Intraocular pressure may be very elevated related to neovascular glaucoma, or low, even with rubeosis, due to ciliary ischemia. At ocular fundus examination, venous dilatation, arteriolar narrowing are usually seen, with hemorrhages and occasionally papillary edema and proliferative retinopathy in advanced cases [4]. Fluorescein angiography shows delayed choroidal filling in early phases with prolonged arteriovenous transit time. Diagnosis of the atherosclerotic carotid stenosis is made by Carotid imaging (Doppler ultrasonography, Magnetic resonance angiography). Management of the disease is difficult, and needs collaboration between ophthalmologist, cardiologist and cardiovascular surgeon [2].

Ocular treatment is directed towards the treatment of anterior segment inflammation, control of retinal ischemia, and the treatment of raised intraocular pressure and neovascular glaucoma. Since ocular ischaemic syndrome is usually an indicator of carotid artery stenosis, patients should be referred for neurological and cardiovascular assessment. Carotid endarterectomy has been shown to benefit patients with symptomatic cerebral ischemia when there is greater than 70% carotid artery stenosis [5].

Conclusion

In conclusion, Ocular ischemic syndrome is an uncommon but potentially blinding condition that may be misdiagnosed. Ocular manifestations in elderly patients, especially with cardiovascular risk factors, should be referred for neurological and cardiovascular assessment.

References

1. Luo J, Yan Z (2018) Clinical analysis of 42 cases of ocular ischemic syndrome. *J ophthalmol* 2018: 2606147.
2. Malhotra R, Gregory-Evans K (2000) Management of ocular ischaemic syndrome. *Ue Br J ophthalmol* 84: 1428-1431.
3. Dugan JD (1991) Green WR: Ophthalmologic manifestations of carotid occlusive disease. *Eye* 5: 226-238.
4. Kim YH, Sung MS, Park SW (2017) Clinical features of ocular ischemic syndrome and risk factors for neovascular glaucoma. *Korean J ophthalmol* 31: 343-350.
5. MRC European Carotid Surgery Trial (1991) Interim results for symptomatic patients with severe (70-99%) or with mild (0-29%) carotid stenosis. European Carotid Surgery Trialists' Collaborative Group. *Lancet* 337: 1235-1243.