

## Outcomes of Endocyclophotocoagulation in Patients with Cataract and Open-Angle Glaucoma at Oftalmosalud Eye Institute, Lima, Peru

Juan Carlos Izquierdo Villavicencio\*, Ana Luisa González Méndez, Imelda Ramírez Jiménez, Fabiola Patricia Quezada Baltodano, Roció Cecilia Araujo Segura, Lukas Saldarriaga Franco and María Corina Ponte-Dávila

Department of Ophthalmology, Research Department Oftalmosalud Eye Institute, Lima-Peru, Av. Javier Prado Este 1142, San Isidro, Lima, Perú

\*Corresponding author: Juan Carlos Izquierdo Villavicencio, MD, Chief of Glaucoma, Department of Ophthalmology, Research Department Oftalmosalud Eye Institute, Lima-Peru, Av. Javier Prado Este 1142, San Isidro, Lima, Perú, Tel: +511-985-148-485; E-mail: jcizq@mac.com

Received: Apr 05 2024; Accepted: May 20 2024; Published: May 25, 2024; DOI: 10.59462/jedt.1.1.104

Citation: Villavicencio JCI, Méndez ALG, Jiménez IMR, Baltodano FPQ, Segura RCA, et al. (2024) Outcomes of Endocyclophotocoagulation in Patients with Cataract and Open-Angle Glaucoma at Oftalmosalud Eye Institute, Lima, Peru. Journal of Eye Disorders and Therapy, 1(1):104.

Copyright: ©2024 Villavicencio JCI, et al. This is an open-access article distributed under the terms of the Creative Commons Attribution License, which permits unrestricted use, distribution, and reproduction in any medium, provided the original author and source are credited.

### Abstract

**Purpose:** To describe the clinical results of the endocyclophotocoagulation (ECP) in patients with Cataract and Open-angle glaucoma with 2 years follow up (Lima, Peru).

**Methods:** A retrospective study, included 41 eyes that evaluates the results of the Phaco+ECP performed 2011 and 2013 at Oftalmosalud Eye Institute in Lima, Peru. It was evaluated best corrected visual acuity (BCVA) and intraocular pressure (IOP) preoperatively and 1 day, 1 month, 6 months, 1 year, and 2 years after ECP, and the number of anti-glaucomatous drugs administered was noted preoperatively and at 1 and 2 years after surgery.

Success rate was defined as IOP  $\leq$  18 mmHg with or without medication at 1 and 2 years postop.

**Results:** The mean BCVA was  $0.7 \pm 0.6$  preoperatively,  $1.0 \pm 0.8$  at day 1,  $0.4 \pm 0.5$  at 1 month,  $0.3 \pm 0.5$  at 6 months,  $0.3 \pm 0.5$  at 1 year, and  $0.3 \pm 0.5$  at 2 years. A significant difference in the preoperative BCVA value was observed in comparison with 1day post op, but not difference was found between the preoperative value and the control at 1 and 2 years. Mean intraocular pressure was  $22.0 \pm 8.3$  mmHg preoperatively,  $16.0 \pm 6.5$  mmHg at 1 day,  $15.4 \pm 5.4$  mmHg at 1 month,  $14.0 \pm 4.5$  mmHg at 6 months,  $13.7 \pm 3.3$  mmHg at 1 year, and  $12.9 \pm 2.3$  mmHg at 2 years. The reduction of the intraocular pressure from the preoperative period and the control at 2 years was statistically significant. The mean number of antiglaucomatous drugs administered, had a significantly decrease from  $2.08 \pm 0.87$  to  $1.60 \pm 0.94$  at pre and 2 year follow up respectively

**Conclusion:** ECP is a treatment that reduces IOP in patients with cataract and open-angle glaucoma.

**Keywords:** Endocyclophotocoagulation; Best corrected visual acuity; Intraocular pressure; Ciliary processes

### Introduction

The use of cyclodestructive procedures began in the 1940s with diathermy, followed in the late 1960s with the invention of cryotherapy with ruby Nd:YAG laser. Ultrasound was first used in 1985, and recent advances include high-intensity-focused ultrasound and transscleral cyclophotocoagulation with an 810-nm semiconductor diode G-probe laser [1,2]. Although cyclocryotherapy and cyclophotocoagulation lower intraocular pressure (IOP), these techniques have a high rate of complications such as hypotonia, pthisis bulbi, and decreased visual acuity in patients who already have compromised vision, which is why both techniques are only used in end-stages of glaucoma [3-5].

Endocyclophotocoagulation (ECP) is a method of cyclodestruction that allows the direct photocoagulation of the ciliary body under endoscopic visualization [6,7]. In this technique, the ciliary processes are directly ablated by the application of a diode laser to reduce the production of aqueous humor [8-13]. ECP has as main indication for treatment of refractory glaucoma, and recent studies report its use in moderate and advanced glaucoma due to its efficacy and good tolerance [14]. Most of the studies about this topic have been carried out in the Asian population and in North America [13,14]. Very few

studies have been conducted in other ethnic groups with greater pigmentation as Latin American people. There are differences in the pigmentation of the ciliary epithelium, and this could affect the amount of laser energy required to achieve the same effect in different races [3,14]. Knowing that the laser is absorbed by the Pigment Epithelium, it is important to establish the parameters of the Laser in a population with greater pigmentation [15-17].

ECP is indicated for the treatment in eyes that are still visually functional with a low complication rate [18]. In this study, we describe our Latin American Experience, in Lima Peru with ECP in the treatment of open angle glaucoma.

### Methods

This study is retrospective-longitudinal that was carried out in 41 eyes of 41 patients diagnosed with open-angle glaucoma between 2011 and 2013 at Oftalmosalud Eye Institute in Lima, Peru. All patients gave written approval to the medical ethics committee for the use of information from clinical records, in accordance with the guidelines of the Declaration of Helsinki.

We included patients with cataract and open-angle glaucoma, the combined cataract phacoemulsification and ECP surgery were performed. Exclusion criteria were a follow-up of less than 24 months,

NPL, narrow angle glaucoma. All the patients had mild or moderate Glaucoma by the Hodapp-Parrish –Anderson Visual Field Classification (-6 to >-12 Db)

We evaluated the best corrected visual acuity (BCVA) using a Snellen card and Logmar scale. Ue IOP was measured with a Goldman tonometer. Uese variables were measured preoperatively and at 1 day, 1 month, 6 months, 1 year, and 2 years postoperatively. Ue number of antiglaucomatous drugs was assessed during the preoperative period and at 6 months, 1 year, and 2 years postoperatively. Intraoperative and postoperative complications were recorded. Ue patients who did not undergo all postoperative controls were excluded. Ue rate of success, defined as a decrease in IOP to less than 18 mmHg with or without drugs.

### Surgical Technique

We used the Endoscopic Laser Endoscopy manufactured by Endo Optics, Beaver-Visitec International. It used Diode Laser of 810 nm on continuous wave mode; the laser power level was 0.2 Watt. We use a 20-gauge curved endoscope that has inside a xenon light sources, a video camera, and a fiber optics laser (Figure 1).

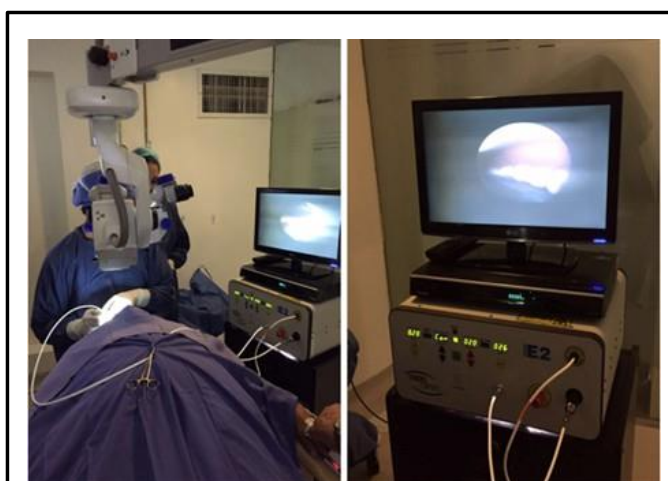


Figure 1: Endoscopic Diode Laser unit manufactured by Endo Optics. It used diode laser of 810 nm on continuous wave mode, the laser power level was 0.2 Watt.

First, we made the Phacoemulsification with clear corneal incisions, aler we implant the intraocular lens, we filled the sulcus with cohesive viscoelastic to better visualize the ciliary process. We centered the image and introduced the laser endoscope through the principal corneal incision and through the pupillary space until we could visualize 5-6 ciliary processes (Figure 2). At this point we are at 2-3 mm to the ciliary processes. Overtreatment, characterized by tissue explosion ("popping"), is avoided. Ue laser was applied in the entire length of the process until it whiteness and shrinkage. We also used the expand paracentesis incision to complete 360 degrees.

Ue viscoelastic is completely removed from the eye using irrigation/aspiration. At the end of surgery, we injected 0.1 mm of triamcinolone in the anterior chamber.

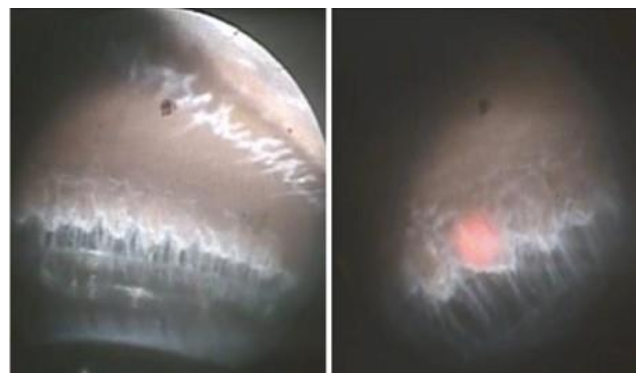


Figure 2: Endoscopic view of the five or six ciliary processes during ECP. Ue laser is applied until we see shrinkage and whitening of the tissue, while avoiding ciliary process explosion (popping).

### Postoperative Care and Medication

Ue patients were treated postoperatively with topical antibiotic for 15 days. Topical steroid drops were taken every 4 h for the first week, every 6 h second week and every 8 h the third and fourth week aler the surgery. Patients also received atropine every 8 h for 2 weeks. We used glaucoma medication if the IOP was >18 mmHg. We were adding Timolol, then Dorzolamide and Brimonidine according to the IOP value.

### Statistical analysis

Data were analyzed by using the SPSS software ver [21], using the Wilcoxon signed ranks test to assess BCVA results and Student's t-test to analyze IOP and number of antiglaucomatous drugs. A P value<0.05 was considered to indicate a significant di9erence.

### Results

Our study included 41 eyes of 41 patients with primary open-angle glaucoma. Were 28 men (68.3%) and 13 women (31.7%), with a mean age ( $\pm$  SD) of  $67.7 \pm 13.9$  years. All the cases underwent phacoemulsification plus ECP. Demographic and clinical characteristics of participants were described (Table 1).

Phacoemulsification+ECP	No %
No. of patients	41 (100)
Sex	
Female	13 (31.7%)
Male	28 (68.3%)
Age of patients (years)	
Mean $\pm$ SD	$67.7 \pm 13.9$
No. of eyes	41 (100%)
Right	23 (56.1%)
Left	18 (43.9%)

Diagnosis	
Chronic open-angle glaucoma	41 (100%)

Table 1: Demographic and clinical characteristics of participants.

### Visual acuity

Ue mean BCVA ( $\pm$  SD) preoperative was  $0.7 \pm 0.6$ , at 1 year  $0.3 \pm 0.5$  and at 2 years of the postoperative was  $0.3 \pm 0.5$ ; (Table 2 and Figure 3). At 2 year follow up the BCVA improved in 29 eyes (58%), remained the same in 7 eyes (14%), and decreased in 14 eyes (28%).

	Mean $\pm$ SD	*P value
BCVA pre	$0.7 \pm 0.6$	
BCVA 1 day	$1.0 \pm 0.8$	<0.001
BCVA 1 month	$0.4 \pm 0.5$	<0.001
BCVA 6 months	$0.3 \pm 0.5$	<0.001
BCVA 1 year	$0.3 \pm 0.5$	<0.001
BCVA 2 year	$0.3 \pm 0.5$	<0.001
IOP pre	$22.0 \pm 8.3$	
IOP 1 day	$16.0 \pm 6.5$	<0.001
IOP 1 month	$15.4 \pm 5.4$	<0.001
IOP 6 month	$14.0 \pm 4.5$	<0.001
IOP 1 year	$13.7 \pm 3.3$	<0.001
IOP 2 year	$12.9 \pm 2.3$	<0.001

Table 2: Statistical results of patients undergoing to faco+endocyclophotocoagulation; \*P value (&lt;0.05).

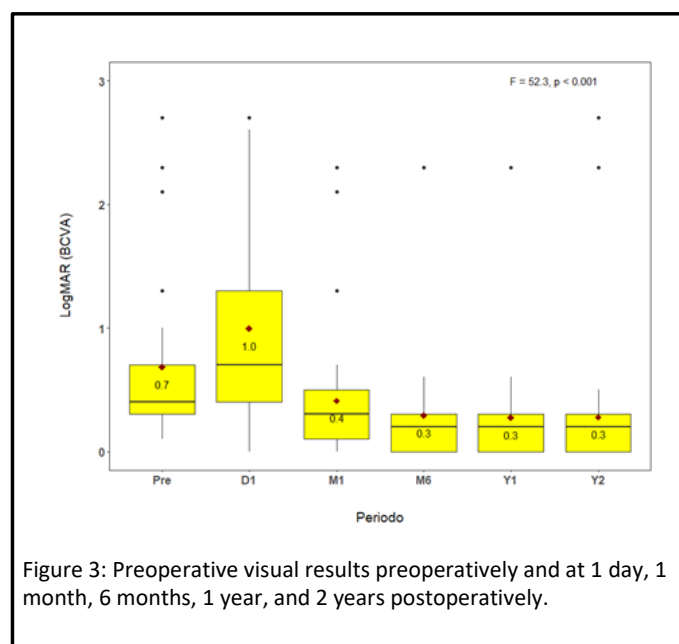


Figure 3: Preoperative visual results preoperatively and at 1 day, 1 month, 6 months, 1 year, and 2 years postoperatively.

### IOP

Ue mean IOP ( $\pm$  SD) was  $22.0 \pm 8.3$  mmHg preoperative,  $13.7 \pm 3.3$  mmHg at 1 year, and  $12.9 \pm 2.3$  mmHg at 2 year. (Table 2 and Figure 4). Comparing the mean preoperative IOP and 2 years postoperative, the difference was statistically significant at all follow-up intervals with one (P<0.001). We found an IOP reduction of 36, 7% at 1-year follow-up and a 41, 1% at 2 years follow up.

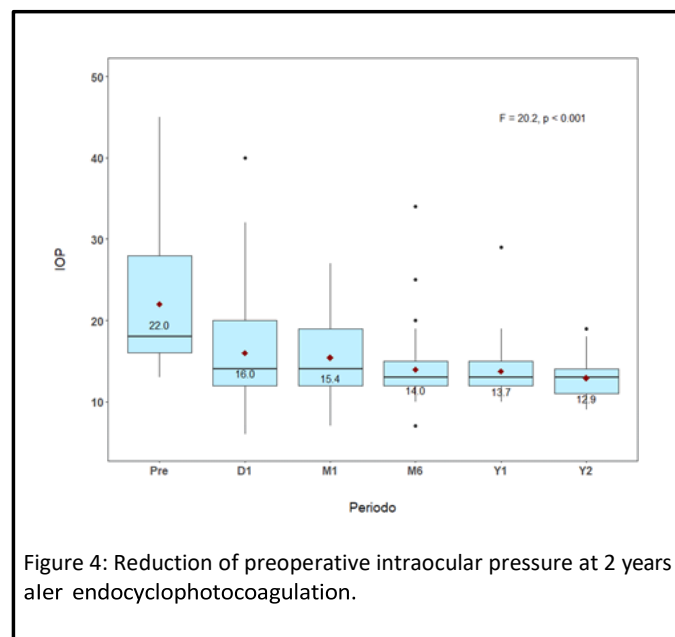


Figure 4: Reduction of preoperative intraocular pressure at 2 years after endocyclophotocoagulation.

### Medication

Ue mean  $\pm$  SD values of antiglaucomatous drugs significantly decreased from  $2.08 \pm 0.87$  to  $1.60 \pm 0.94$  at 2 years. In the preoperative period 90% (37) of the eyes used more than one antiglaucomatous drugs. At one year follow up 70.7% (29) of the eyes used more than one drugs. At 2-year follow-up, only 51% (25) of the eyes used more than one antiglaucomatous drug, which was a statistically significant decrease (P < 0.001) (Figure 5).

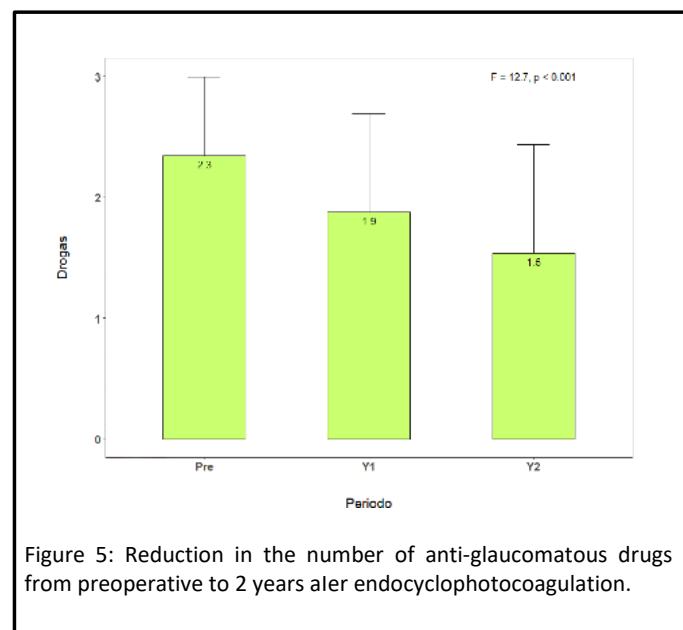
Postoperative complications were hemorrhagic choroidal detachment in 1 eye (2%), serous choroidal detachment in 1 eye (2%), pupillary membrane in 6 eyes (12%), and corneal rejection in 1 eye (2%); and 32 eyes (82%) did not present complications.

### Discussion

Ue purpose of our study was to describe clinical outcomes in patients with glaucoma treated with ECP. Uis series had a high rate of success in reducing IOP.

We found a rate of success of 86% at first year and 85% at two years, and the IOP reduction was 36,7% at 1year follow- up and a 41, 1% at 2-year follow- up. Similar studies found similar IOP reduction, Lima et al with 47% and Kahook et al 40% at two year follow up [14] However, another Asian study [13] reported IOP reduction of 18% at the second year follow up [14]. Most of the studies are reported from North America, our study is made in Latin American patients (Peru) and our result is very similar with the North American studies. Uis difference in the IOP reduction at 2 years follow up may be explained by the difference on the ciliary body pigmentation among races; the same

laser power does not have the same effect on the ciliary body, causing faster regeneration and increasing the IOP over the time [13].



In our outcomes, we found decrease of BCVA during the first month; it could be due to the postop inflammation induced either by the phacoemulsification or by the well-known inflammation that a laser produces during the early postoperative period, both was resolved with steroids during the first month postop.

We found significant difference in the BCVA at 1 year and 2 years. At 2 years, we found that the BCVA only decreased in 14 eyes (28%); 6 eyes (46%) of this group had chronic open-angle glaucoma and 8 eyes (56%) were secondary glaucoma (i.e., 6 eyes, postpenetrating keratoplasty; 2 eyes, pseudoexfoliative glaucoma).

ECP can be used as a first-line procedure in combination with cataract surgery in patients without advanced glaucoma and no previous surgery. Berke et al. [19] reported a series cases with no previous surgery with open-angle glaucoma plus cataract; they compared 625 eyes of phacoemulsification+ECP and 81 eyes phacoemulsification control groups. The number of postoperative drugs and the IOP value were lower in those who underwent the combined surgery. Complications were similar for both groups; they had cystoid macular edema in less than 1% of cases. Gayton et al. [20] compared the efficacy of trabeculectomy vs. ECP. In the trabeculectomy group, IOP was controlled without medication in 42% and with medication in 54% of cases. In the ECP group, the IOP was controlled without medication in 30% and with medication in 65% of the cases. During the postoperative controls, the eyes that underwent ECP surgery had less inflammation than the trabeculectomy group. Another study compared ECP efficacy with that of Ahmed implants in refractory glaucoma; they achieved >70% success in both groups, with no significant differences between them [8].

In our study, the most frequent complication was pupillary membrane (12%) at 1 month, which could be controlled with topical steroid drugs. In the study by Kaplowitz et al., [21] the most frequent complications observed were fibrin net in 22% of 539 cases, [5] hyphema in 11% of 68 cases, [14] and cystoid macular edema in 10%

of 539 cases [15]. All these complications were resolved with medical treatment before 3 months postoperatively.

## Conclusion

In conclusion, our findings indicate that ECP provides a significant decrease in IOP, without variation of visual acuity, with a low rate of complications and reoperations, and it could be performed alone or in combination with cataract surgery.

## References

- Kraus CL, Tychsen L, Lueder GT, Culican SM (2014) Comparison of the effectiveness and safety of transscleral cyclophotocoagulation and endoscopic cyclophotocoagulation in pediatric glaucoma. *J Pediatr Ophthalmol Strabismus* 51: 120-127.
- Murphy CC, Burnett CA, Spry PGD, Broadway DC, Diamond JP (2003) A two centre study of the dose-response relation for transscleral diode laser cyclophotocoagulation in refractory glaucoma. *Br J Ophthalmol* 87: 1252-1257.
- Izgi B, Demirci H, Demirci FY, Turker G (2001) Diode laser cyclophotocoagulation in refractory glaucoma: comparison between pediatric and adult glaucomas. *Ophthalmic Surg Lasers* 32: 100-107.
- Jacobi PC, Dietlein TS (2000) Endoscopic surgery in glaucoma management. *Curr Opin Ophthalmol* 11: 127-132.
- Murthy GJ, Murthy PR, Murthy KR, Kulkarni VV, Murthy KR (2009) A study of the efficacy of endoscopic cyclophotocoagulation for the treatment of refractory glaucomas. *Indian J Ophthalmol* 57: 127-132.
- Čanadanović V, Tušek-Lješević L, Miljković A, Barišić S, Bedov T, et al. (2015) Effect of diode laser cyclophotocoagulation in treatment of patients with refractory glaucoma. *Vojnosanit Pregl* 72: 16-20.
- Uram M (1995) Endoscopic cyclophotocoagulation in glaucoma management. *Curr Opin Ophthalmol* 6: 19-29.
- Lima FE, Magacho L, Carvalho DM, Susanna R, Avila MP (2004) A prospective, comparative study between endoscopic cyclophotocoagulation and the Ahmed drainage implant in refractory glaucoma. *J Glaucoma* 13: 233-237.
- Seibold LK, Soohoo JR, Kahook MY (2015) Endoscopic cyclophotocoagulation. *Middle East Afr J Ophthalmol* 22: 18-24.
- Falkenberry SM, Siegfried CJ (2009) Endocyclophotocoagulation. *Middle East Afr J Ophthalmol* 16: 130-133.
- Neely DE, Plager DA (2001) Endocyclophotocoagulation for management of difficult pediatric glaucomas. *J AAPOS* 09 Publ Am Assoc Pediatr Ophthalmol Strabismus 5: 221-229.
- Lin S (2002) Endoscopic cyclophotocoagulation. *Br J Ophthalmol* 86: 1434-1438.
- Yip LW, Yong SO, Earnest A, Ji J, Lim BA (2009) Endoscopic cyclophotocoagulation for the treatment of glaucoma: an Asian experience. *Clin Experiment Ophthalmol* 37: 692-697.
- Chen J, Cohn RA, Lin SC, Cortes AE, Alvarado JA (1997) Endoscopic photocoagulation of the ciliary body for treatment of refractory glaucomas. *Am J Ophthalmol* 124: 787-796.
- Lima FE, Beniz Neto J, Toscano D, Carvalho DM de, Ávila MP de (2009) Endoscopic cyclophotocoagulation in refractory glaucomas: a long term study. *Rev Bras Otolalol* 68: 146-151.
- Francis BA, Kawji AS, Vo NT, Dustin L, Chopra V (2011) Endoscopic cyclophotocoagulation (ECP) in the management of uncontrolled glaucoma with prior aqueous tube shunt. *J Glaucoma* 20: 523-527.
- Raizada S, Al Sabti K (2009) A study of the efficacy of endoscopic cyclophotocoagulation for the treatment of refractory glaucomas. *Indian J Ophthalmol* 57: 406-407.
- Zarco BD, Ramos RIMT y, Ortega VK (2008) Endociclofotocoagulación en pacientes con glaucoma refractario. Experiencia en el Instituto de Oftalmología Fundación Conde de Valenciana. *Acta Médica Grupo Ángeles* 6: 103-106.

19. Comb Phaco ECP Berke (2017) pdf.[http://www.endooptiks.com/articles/Comb\\_Phaco\\_ECP\\_Berke.pdf](http://www.endooptiks.com/articles/Comb_Phaco_ECP_Berke.pdf). Accessed.
20. Gayton JL, Van Der Karr M, Sanders V (1999) Combined cataract and glaucoma surgery: trabeculectomy versus endoscopic laser cycloablation. *J Cataract Refract Surg* 25: 1214-1219.
21. Kaplowitz K, Kuei A, Klenofsky B, Abazari A, Honkanen R (2015) Use of endoscopic cyclophotocoagulation for moderate to advanced glaucoma. *Acta Ophthalmol* 93: 395-401.